

CASE REPORT

Open Access



Sinus arrest associated with diabetic ketoacidosis regressing to sinus rhythm after compensation of diabetic process: a case report and review of literature

Abderrahmane Bouchaala^{1*} , Jaouad Nguadi², Najat Mouine¹, Hicham Bouzelmat² and Aatif Benyass¹

Abstract

Background Diabetic ketoacidosis (DKA) is a serious, life-threatening condition known for its profound hydro electrolytic disturbances and multiple complications, including cerebral edema and circulatory collapse. While this complication is traditionally associated with patients suffering from type 1 diabetes, numerous studies have documented its non-negligible incidence in type 2 diabetics. However, conductive disorders that manifest during its course, such as sinus arrest, are poorly reported and can be life-threatening on their own when not promptly recognized and treated. The primary objective of this report is to increase awareness regarding the uncommon conduction complications associated with diabetic ketoacidosis, even in the absence of overt hyperkalemia, and to underscore the critical significance of early diagnosis and prompt intervention in managing these complications.

Case presentation We present the case of a middle-aged man with past history of type 2 diabetes whose symptoms included asthenia and consciousness disorder concomitant with ketoacidosis decompensation. Electrocardiogram (ECG) revealed the presence of sinus arrest with ventricular escaping rhythm. Rapid management of the diabetic decompensation led to spontaneous restoration of normal sinus rhythm, thus obviating the necessity for permanent pacing in the patient.

Conclusions Atypical complications arising during ketoacidosis decompensation, including conditions like sinus arrest, are frequently overlooked and tend to carry a guarded prognosis. Proper recognition and prompt treatment are imperative to achieve the optimal clinical outcome.

Keywords Diabetic ketoacidosis, Complication, Sinus arrest, Diabetes mellitus

Introduction

Diabetic ketoacidosis (DKA) is a frequent acute complication of diabetes mellitus, characterized by the combination of hyperglycemia, hyperketonemia, metabolic

acidosis, and subsequently other electrolyte disturbances, such as hyponatremia, dyskalemia, and acute renal failure [1]. Although diabetic ketoacidosis predominantly manifests in individuals afflicted with autoimmune type 1 diabetes, it is noteworthy that a considerable proportion of documented DKA instances pertain to patients with type 2 diabetes, constituting no less than one-third of the cumulative reported cases [2, 3]. If life-threatening complications like hypovolemia and cerebral and pulmonary edema are anticipated in the first place, several others are underestimated and poorly reported in the current literature, among these are conduction disorders

*Correspondence:

Abderrahmane Bouchaala
bouchaalaabderrahmane@gmail.com

¹ Clinical Cardiology Department, Cardiology Center, Mohammed V Military Instruction Hospital of Rabat, Rabat, Morocco

² Rhythmology Department, Cardiology Center, Mohammed V Military Instruction Hospital of Rabat, Mohammed V University, Rabat, Morocco



© The Author(s) 2023. **Open Access** This article is licensed under a Creative Commons Attribution 4.0 International License, which permits use, sharing, adaptation, distribution and reproduction in any medium or format, as long as you give appropriate credit to the original author(s) and the source, provide a link to the Creative Commons licence, and indicate if changes were made. The images or other third party material in this article are included in the article's Creative Commons licence, unless indicated otherwise in a credit line to the material. If material is not included in the article's Creative Commons licence and your intended use is not permitted by statutory regulation or exceeds the permitted use, you will need to obtain permission directly from the copyright holder. To view a copy of this licence, visit <http://creativecommons.org/licenses/by/4.0/>.

[4], which can be explained by the negative chronotropic effect of protons on nodal cells and the potentiation of hyperkalemia within the same tissue [5, 6]. We report a rare case of middle-aged man who presented symptomatic sinus arrest concomitant with diabetic ketoacidosis decompensation returning to sinus rhythm once the acute metabolic disorder is controlled.

Case presentation

In a 51-year-old man with a 7-year history of type 2 diabetes on oral antidiabetic drugs (Metformin 500 mg b.i.d) who had been previously hospitalized twice for ketoacidosis decompensations, the first occurrence was in April 2018 and was attributed to a severe pulmonary infection, while the second decompensation took place in August 2020 when the patient abruptly discontinued his treatment and lifestyle management, presented to the emergency department for fluctuating sluggishness, asthenia, diffuse abdominal pain, and vomiting. At the time of arrival, antidiabetic medication consisted solely of metformin 500 mg twice a day, without any other hypoglycemic treatment. The baseline glycated hemoglobin (A1c) level was 8.7%.

Four days before his presentation, the patient experienced urinary burning with fever. Clinical examination on admission found a somnolent patient, febrile with body core temperature of 38.1 °C, polypneic at 27 breaths per minute with correct room air saturation SpO₂: 98%, and his blood pressure figures were 97/61 mmHg and heart rate varying between 20 and 40 bpm with no signs of heart failure or peripheral hypoperfusion. The patient's weight was 89 kg, and height was 171 cm, resulting in a body mass index of 30.4 kg/m². Cardiac, pulmonary, and arterial auscultations were unremarkable. Abdominal examination found diffuse tenderness without specific localization of pain or hepatosplenomegaly; the hernial orifices were free. Other systemic examinations were normal.

The blood analysis in emergency room showed hyperglycemia at 6.1 g/L, acetone (3+), and urinary glucose (2+) were detectable with urine dipsticks; in addition, a blood gas analysis revealed a metabolic acidosis with high anion gap (Table 1). Inflammation markers were elevated (white blood cells: 15,500/μL, neutrophils: 12,400/μL, C-reactive protein: 117 mg/dL, procalcitonin: 1.5 μg/L), normal lactate levels were observed, and there were no abnormalities detected in liver, thyroid, and renal functions (Table 1). The diagnosis of ketoacidosis decompensation was confirmed, and an investigation into potential triggering factors commenced. The initial ECG revealed sinus arrest accompanied by a ventricular escape rhythm exhibiting fluctuations in heart rate between 20 and 40 bpm (Fig. 1).

Table 1 Biological parameters on admission to emergency room

Variable	Result
Sodium (mmol/L)	136
Potassium (mmol/L)	5.3
Chloride (mmol/L)	96
Calcium (mg/dL)	10.7
Blood glucose (mg/dL)	6.1
Serum bicarbonate (mmol/L)	17
Urea (g/L)	0.36
Creatinine (mg/L)	11.6
ASAT (U/L)	24
ALAT (U/L)	19
GGT (U/L)	35
Lactates (mmol/L)	1.2
pH	7.24
pO ₂ (mmHg)	122
pCO ₂ (mmHg)	31
Anion gap	28.7
CRP (mg/dL)	117
Procalcitonin (μg/L)	1.5
TSH (mIU/L)	3.6
FT4 (ng/dL)	1.1
White blood cells (μL)	15,500
Neutrophils (μL)	12,400
Hemoglobin (g/dL)	14.1
Platelets (μL)	212,000

The patient underwent prompt medical intervention, including intravenous (IV) administration of saline solution for parenteral rehydration, insulin therapy tailored to body weight as per the diabetic ketoacidosis protocol, aiming at correcting acidosis and averting hypokalemia. While the implantation of endocavitary cardiac pacing was considered, the patient received a single bolus of 0.06-mg IV isoproterenol to prevent extreme bradycardia and maintain proper cerebral perfusion. Noteworthy, the improvement in the patient's conduction abnormalities became evident within the first hour of medical management, leading to the restoration of a regular sinus rhythm as evidenced by the ECG (Fig. 2). The transthoracic echocardiography did not reveal any significant abnormalities.

The clinical course was characterized by the full restoration of the baseline level of consciousness, improvement in hemodynamic parameters, and a sustained return to a regular sinus rhythm, as illustrated in Fig. 3. The identification of *Escherichia coli* as a triggering factor led to the administration of intravenous ceftriaxone for the treatment of a urinary tract infection. Subsequently, the patient was referred to the endocrinology department where he received therapeutic education and modification to his antidiabetic

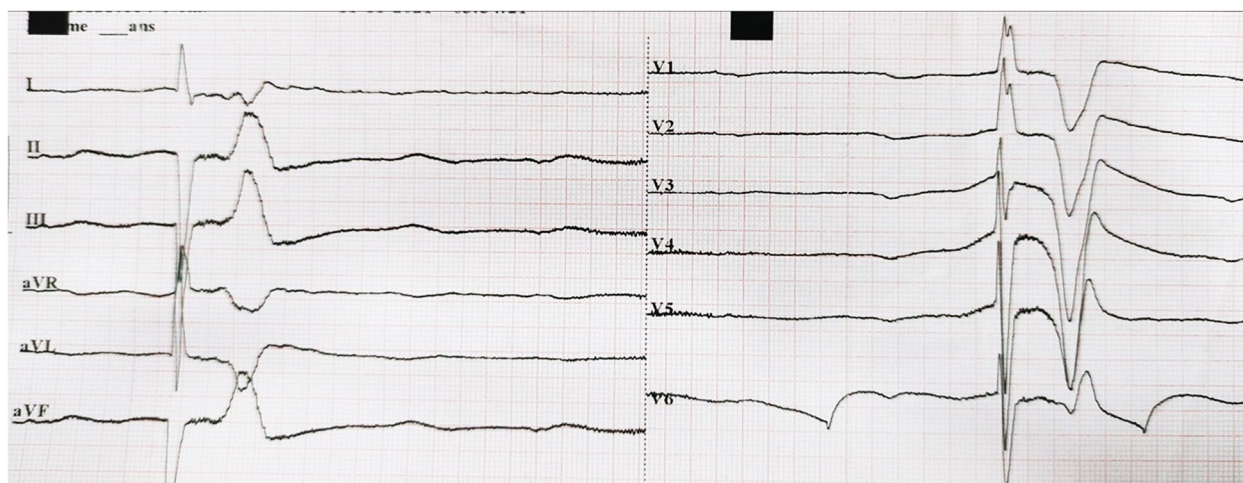


Fig. 1 Initial ECG showing sinus arrest with ventricular escape rhythm

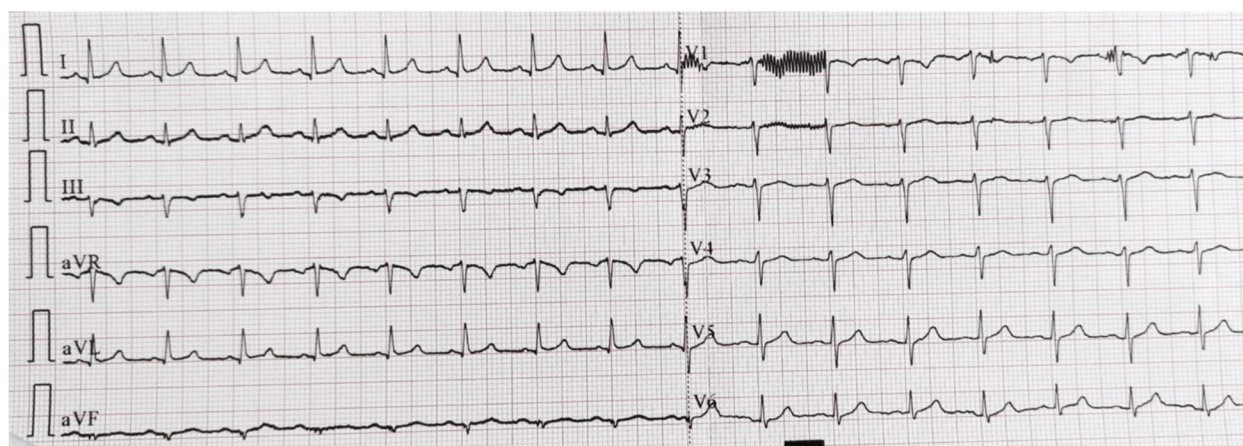


Fig. 2 Spontaneous return to sinus rhythm

treatment; the patient was switched to an insulin basal-bolus regimen in combination with metformin 500 mg t.i.d. and subsequently discharged to continue recovery at home on the fifth day of hospitalization.

One week following the initial assessment, a comprehensive review was conducted. During this follow-up, the patient's vital signs, including heart rate, blood pressure, respiratory rate, and temperature, remained stable within normal ranges. Electrocardiography results continued to show a regular sinus rhythm. Additionally, a coronary angiography was conducted, yielding normal results, and laboratory assessments indicated normal levels of electrolytes, blood glucose, and well-maintained renal and hepatic functions.

Discussion

This case serves as confirmation that diabetic ketoacidosis can manifest as a disturbance in consciousness primarily attributed to conduction disorders, as exemplified by the occurrence of sinus arrest in our particular case. Sinus arrest (also known as sinoatrial arrest or sinus pause) is defined by a total cessation of electric impulses originating from the sinus node; although asymptomatic arrests less than 3 s can occur in normal people, especially in athletes or during the sleep, arrest longer than 3 s may be associated with symptoms and related to sinus node dysfunction [7]. While several etiologies of this condition have been identified and categorized into two main groups, intrinsic (e.g., myocardial infarction,

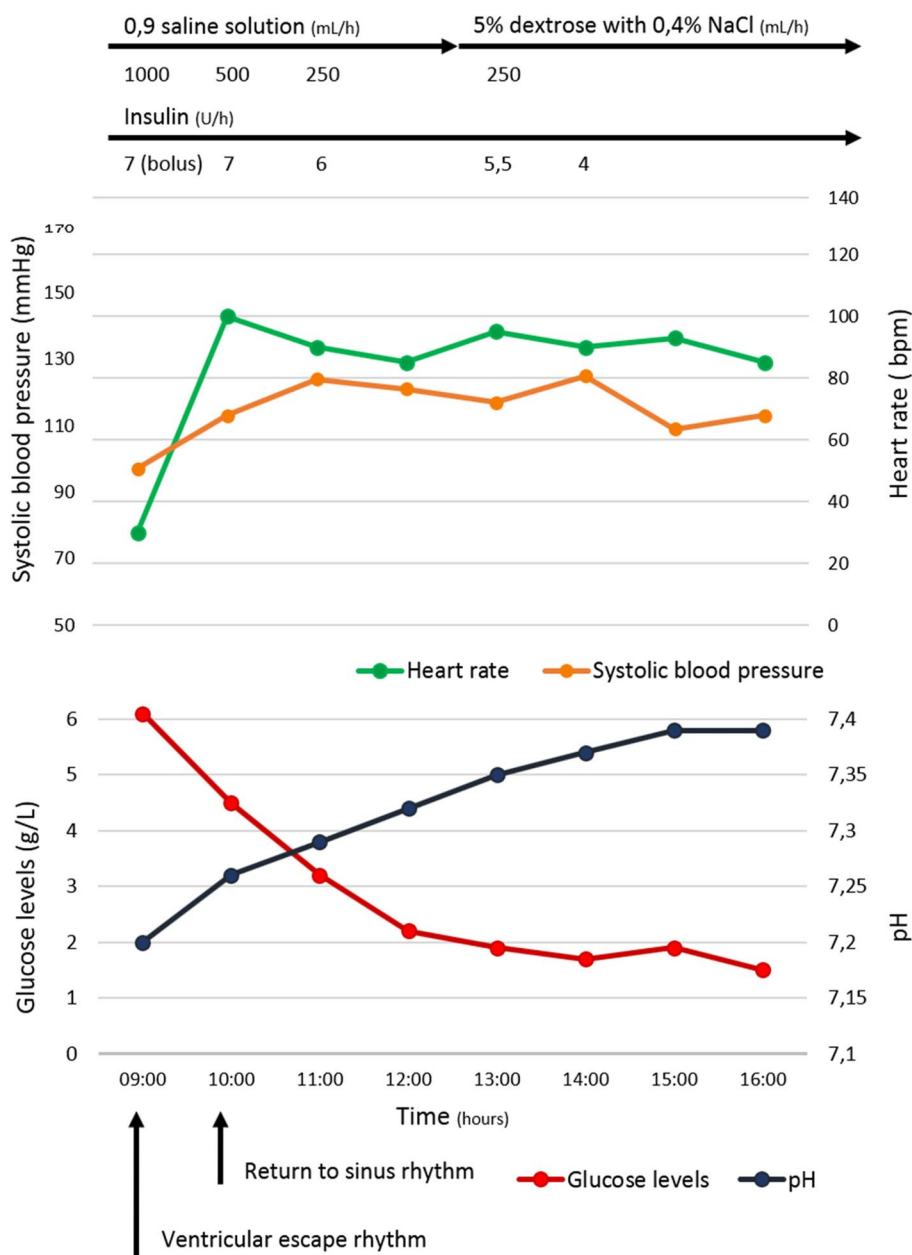


Fig. 3 Clinical and biological parameters evolution

idiopathic degenerative fibrosis, cardiac remodeling, and infiltrative heart diseases) and extrinsic (e.g., endocrine, metabolic, drug-induced, and toxic causes), metabolic acidosis remains a presumed yet poorly elucidated etiology, thus accentuating the significant value of this case report, taking into consideration that our patient had a potassium level at the upper limit and a clear-cut metabolic acidosis [8].

The association of metabolic abnormalities, particularly acidosis, with conduction disorders during

ketoacidosis is a scarcely described phenomena in literature. Manappallil and Nambiar reported a case involving a 58-year-old diabetic female who was diagnosed with diabetic ketoacidosis and acute kidney injury. The patient presented with a severe metabolic acidosis (pH of 7.04) and hyperkalemia (8.5 mEq/L). The electrocardiogram (ECG) revealed sinus bradycardia progressing rapidly to asystole, resulting in cardiac arrest that was successfully resuscitated. The patient exhibited a favorable outcome following treatment under diabetic ketoacidosis

protocols, avoiding the need for pacemaker implantation [9]. A similar observation of reversibility with medical treatment was made by Anno and his colleagues who reported the case of a 73-year-old woman with a cardiac pacemaker, experiencing sinus dysfunction concomitant with diabetic ketoacidosis decompensation [10]. Ziliotto described a total atrioventricular block occurring during the course of diabetic ketoacidosis decompensation, which resolved to sinus rhythm within months of insulin therapy [11].

In a report encompassing two case studies, Goto and his colleagues underscored the profound metabolic acidosis experienced during euglycemic DKA among patients treated with sodium-glucose cotransporter-2 inhibitors (SGLT2is). The second case featured a loss of consciousness and a protracted episode of sinus arrest necessitating the temporary placement of a cardiac pacemaker. Notably, the return to spontaneous sinus rhythm occurred promptly following the successful correction of acidosis and the normalization of serum β -hydroxybutyrate levels [12].

Concerning sinus arrest, its occurrence as a result of electrolyte disturbances is a rare condition, taking into account that the cells of the sinoatrial node are relatively more resistant to hydro-electrolyte disturbances, unlike the less stable atrial or ventricular ones, yet sudden sinus arrest could take place without any other prior symptoms or electrocardiographic signs [5, 13].

Different hypotheses have been suggested to explain the effect of acidosis on nodal cells; the first one is the direct negative chronotropic effect of the acidosis, and this phenomenon is attributed to the protonation of ionic channels. The other mechanism is the potentiation of hyperkalemia; the increased concentration of potassium due to the movement from cells in exchange for hydrogen ions depresses the automaticity of sinoatrial node cells, and the disappearance of sinoatrial waves is usually seen when serum potassium exceeds 8.0 mEq/L [5, 6].

First-line management for patients presenting confirmed sinoatrial arrest is permanent pacemaker placement with atrial-based pacing, yet investigation for secondary etiology is essential as this disorder may disappear with the correction of its cause. In our case, the restoration of euvoledmia end electrolyte equilibrium resulted in sinus rhythm restoration [7, 8].

Conclusions

Diabetic ketoacidosis remains a common emergency necessitating prompt diagnostic and therapeutic intervention. While altered consciousness is frequently attributed to cerebral edema, it may also be associated with cerebral hypoperfusion resulting from conduction disorders, such as sinus arrest, as seen in our case. Therefore,

clinicians should remain vigilant regarding this clinical presentation and refer to contemporary literature to ascertain the optimal management approach.

Abbreviations

DKA	Diabetic ketoacidosis
ECG	Electrocardiogram
SpO ₂	Peripheral oxygen saturation
cpm	Cycle per minute
bpm	Beat per minute

Acknowledgements

Not applicable.

Authors' contributions

AB conceived the idea to report the case and was responsible for manuscript's writing. AB and JN analyzed the data and were contributors in editing the manuscript. NM, HB and AB supervised and reviewed this work. The final paper has been reviewed and approved by all authors.

Funding

None.

Availability of data and materials

Not applicable.

Declarations

Ethics approval and consent to participate

Not applicable.

Consent for publication

Written informed consent was obtained from the patient to allow publishing a report of his case for educational purposes.

Competing interests

The authors declare that they have no competing interests.

Received: 3 October 2023 Accepted: 18 December 2023

Published online: 02 January 2024

References

- Karslioglu French E, Donihi AC, Korytkowski MT (2019) Diabetic ketoacidosis and hyperosmolar hyperglycemic syndrome: review of acute decompensated diabetes in adult patients. *BMJ (Clinical research ed)* 365:l1114
- Fayfman M, Pasquel FJ, Umpierrez GE (2017) Management of hyperglycemic crises: diabetic ketoacidosis and hyperglycemic hyperosmolar state. *Med Clin North Am* 101(3):587–606
- Lin MV, Bishop G, Benito-Herrero M (2010). Diabetic ketoacidosis in type 2 diabetics: a novel presentation of pancreatic adenocarcinoma.
- Carrizales-Sepúlveda EF, Vera-Pineda R, Jiménez-Castillo RA, Violante-Cumpa JR, Flores-Ramírez R, Ordaz-Farías A (2020) The heart in diabetic ketoacidosis: a narrative review focusing on the acute cardiac effects and electrocardiographic abnormalities. *Am J Med Sci* 361(6):690–701
- Mehta NJ, Chhabra VK, Khan IA (2001) Sinus arrest or sinoventricular conduction in mild hyperkalemia. *J Emerg Med* 20(2):163–164
- Sato H, Seyama I (1986) On the mechanism by which changes in extracellular pH affect the electrical activity of the rabbit sino-atrial node. *J Physiol* 381:181–191
- Issa ZF, Miller JM, Zipes DP (2019). *Clinical Arrhythmology and Electrophysiology* (Third Edition). Elsevier. 8 - Sinus node dysfunction. 238–254.
- Hawks MK, Paul MLB, Malu OO (2021) Sinus node dysfunction. *Am Fam Physician* 104(2):179–185

9. Manappallil RG, Nambiar J (2020) Hyperkalemic cardiac arrest in a patient with diabetic ketoacidosis. *Indian J Crit Care Med* 24(8):737–738
10. Anno T, Tsujimoto K, Shigemoto R, Kojima S, Kaneto H (2021) Diabetic ketoacidosis and sinus arrest conditions in a patient with an inserted cardiac pacemaker. *Acta Diabetol* 58(5):657–660
11. Ziliotto G (1966) Blocco atrio-ventricolare totale insorto in corso di acidosi diabetica risolto completamente dopo tre mesi di terapia insulinica [Total atrio-ventricular block arising in the course of diabetic acidosis which resolved completely after 3 months of insulin therapy]. *Cardiol Prat* 17(2):199–206
12. Goto S, Ishikawa JY, Idei M, Iwabuchi M, Namekawa M, Nomura T (2021) Life-threatening complications related to delayed diagnosis of euglycemic diabetic ketoacidosis associated with sodium-glucose cotransporter-2 inhibitors: a report of 2 cases. *Am J Case Rep* 22:e929773
13. Bonvini RF, Hendiri T, Anwar A (2006) Sinus arrest and moderate hyperkalemia. *Ann Cardiol Angeiol* 55(3):161–163

Publisher's Note

Springer Nature remains neutral with regard to jurisdictional claims in published maps and institutional affiliations.

Submit your manuscript to a SpringerOpen[®] journal and benefit from:

- ▶ Convenient online submission
- ▶ Rigorous peer review
- ▶ Open access: articles freely available online
- ▶ High visibility within the field
- ▶ Retaining the copyright to your article

Submit your next manuscript at ▶ [springeropen.com](https://www.springeropen.com)
