

# Microscopic colitis in Egyptian population: study of some contributing factors and role of chromogranin A as a diagnostic marker

Mohamed S. Gomaa<sup>a</sup>, Ahmad S. Elsayaby<sup>b</sup>, Emad A. Awad<sup>b</sup>,  
Magdy G. Abdel Rahman<sup>b</sup>

<sup>a</sup>Department of Internal Medicine and Gastroenterology, Faculty of Medicine, October 6 University, <sup>b</sup>Department of Internal Medicine and Gastroenterology, Faculty of Medicine, Ain Shams University, Cairo, Egypt

Correspondence to Mohamed Saeed Gomaa, MD, Associate Professor of Medicine, Department of Internal Medicine and Gastroenterology, Faculty of Medicine, October 6 University, Cairo, Egypt; Mob: 01001423269; e-mail: msaeed5@outlook.com

Received 3 June 2017

Accepted 29 June 2017

The Egyptian Journal of Internal Medicine  
2017, 29:164–169

## Background

Microscopic colitis (MC) and irritable bowel syndrome (IBS) have similar symptoms and a normal endoscopic appearance, as well as normal radiologic findings. Several studies have shown that MC can be mistakenly diagnosed as IBS.

Over recent decades, MC has emerged as a common cause of diarrhea, especially in middle-aged or older women, and the disease is regarded as a subgroup within inflammatory bowel disease.

The prevalence of MC in Egyptian patients with chronic watery nonbloody diarrhea is high when compared with that in developed countries. MC mainly affects young and middle-aged patients, and it is more commonly of the lymphocytic type.

Chromogranin A is a common marker for endocrine cells, and the present finding suggests that colonic hormones are involved in the pathophysiology of lymphocytic colitis (LC). The chromogranin cell density seems to be a good diagnostic marker with high sensitivity and specificity in both the right and left colon; thus, sigmoidoscopy can be used in the diagnosis of LC using this marker.

## Aim

The aim of the current work is to study the prevalence of MC among patient presented with symptoms of IBS.

In addition, it is to determine whether chromogranin A cell density is increased in patients with MC and to examine the possibility of using it as a marker for the diagnosis of LC and collagenous colitis.

## Patients and methods

The study was conducted initially on 100 patients presented with symptoms of IBS according to Rome IV criteria. Overall, 50 patients were excluded after finding an organic cause for their symptoms by diagnostic studies.

## Results

A total of 37 cases were diagnosed as having nonspecific colitis, five cases were diagnosed as having MC (10% of the total cases studied), four cases were found to have ulcerative colitis, three cases was found to have eosinophilic colitis, and one case was found to have melanosis coli.

## Conclusion

The initial results of our study revealed that MC is not an uncommon disease, and there was a significant correlation between using NSAID and proton pump inhibitor and smoking, with cases proved to have MC.

## Keywords:

collagenous colitis, irritable bowel syndrome, lymphocytic colitis, Rome IV criteria

Egypt J Intern Med 29:164–169

© 2017 The Egyptian Journal of Internal Medicine  
1110-7782

## Introduction

Microscopic colitis (MC) is characterized by chronic watery diarrhea caused by inflammation in the colon and diagnosed by colonic biopsy. It has a predilection for those who are 60 years or older and comprises two subtypes, lymphocytic colitis (LC) and collagenous colitis (CC); there is a female predominance in the latter [1].

The symptoms of MC are nonspecific, and many patients meet the diagnostic criteria for irritable bowel syndrome (IBS). Therefore, these criteria are

not specific for IBS, and colon biopsies are therefore required to definitively distinguish MC from the much more common IBS [2–4].

As MC can be mistakenly diagnosed as IBS, one of the suggested diagnostic tools to differentiate between the two entities is the use of chromogranin A.

This is an open access article distributed under the terms of the Creative Commons Attribution-NonCommercial-ShareAlike 3.0 License, which allows others to remix, tweak, and build upon the work noncommercially, as long as the author is credited and the new creations are licensed under the identical terms.

Chromogranin A is a common marker for endocrine cells, and recent studies suggest that colonic hormones are involved in the pathophysiology of LC. The chromogranin cell density seems to be a good diagnostic marker with high sensitivity and specificity in both the right and left colon; thus, sigmoidoscopy can be used in the diagnosis of LC using this marker [5].

The current study aims at determining the prevalence of MC in a group of patients presented with symptoms of IBS according to Roma V criteria.

### Patients and methods

This study was conducted in October 6 University Hospitals and Ain Shams University Hospitals on patients who sought medical advice in the GIT clinic for their gastrointestinal (GI) symptoms in the period between February 2016 and December 2016.

The study design (descriptive prevalence study) was approved by the constituted Ethics Committee of the October 6 University, Faculty of Medicine and written consent was obtained from all cases.

The study was conducted initially on 100 patients who presented with symptoms of IBS according to Rome IV criteria [6].

The initially enrolled cases were subjected to history taking including history of any associated illness, drug intake, full clinical evaluation, laboratory tests that included complete blood count, liver and kidney profiles, stool examination and culture, HIV, thyroid-stimulating hormone, tissue transglutaminase (to rule out celiac disease), and tuberculin test.

Ultrasonographical examination was done for all cases to rule out any gross lesion which might cause the symptoms.

Endoscopic studies that were done for all cases included upper GI endoscopy with duodenal biopsy and aspirate; complete colonoscopy examination with multiple biopsies was also done to all cases.

Accordingly, 50 patients were ruled out owing to the presence of significant laboratory abnormalities, abnormalities detected by sonography, and abnormalities detected by upper GI in addition to gross endoscopic abnormalities during colonoscopy.

For the remaining 50 patients (who fulfilled the Rome IV criteria) and after performing complete colonoscopy examination, the obtained biopsies were subjected to the following:

- (1) Hematoxylin–eosin (H&E) for histopathological diagnosis.
- (2) Chromogranin A stain as an immunological marker for staining LC and CC.

All biopsy samples were evaluated and categorized as follows:

- (1) A diagnosis of LC required an increase in intraepithelial lymphocytes to more than 15 lymphocytes/100 epithelial cells, surface epithelial damage with increased lamina propria, plasma cells, and absent or minimal crypt architectural disruption.
- (2) For a diagnosis of CC, an increase/irregularity in subepithelial collagen ( $>10\mu\text{m}$ ) that typically trapped superficial capillaries is required as well as the other inflammatory changes seen in LC [7].

### Results

The initial number of patients enrolled was 100, and after excluding cases with organic disease discovered by examination, laboratory tests, and upper and colonoscopy, the final cases studied were 50 (22 women and 28 men).

All of the remaining 50 patients had normal gross colonoscopy appearance, and histopathologic examination of the 50 patients is shown in Table 1.

On pathological diagnosis of these 50 patients, 37 patients had nonspecific colitis (74% of total).

A total of five patients of MC were reported (one patient has CC and four patients have LC), accounting

**Table 1 Age and pathologic examination of the studied patients**

Groups	N	Mean age	SD	Minimum	Maximum
Nonspecific colitis	37	45.37	14.48	22	78
Microscopic colitis	5	38.80	10.73	21	48
Ulcerative colitis	4	35.00	12.94	21	52
Eosinophilic colitis	3	50.00	15.0	35	65

for ~10% of the total patients (three men accounting for 60% and two women accounting for 40%)

Overall, four patients were diagnosed as having ulcerative colitis and accounted for 8% of the studied population.

Moreover, three patients were diagnosed as having eosinophilic colitis and accounted for 6% of the studied patients.

In addition, one patient was diagnosed as having melanosis coli and accounted for 2% of the studied patients (Tables 2 and 3).

Regarding smoking status in our patients, there is statistically significant difference between the different groups ( $P < 0.05$ ).

In MC group, 60% were smokers versus 40% nonsmokers.

In ulcerative colitis, 50% were smokers versus 50% nonsmokers.

In chronic nonspecific colitis group, 67% were smokers whereas 33% were nonsmokers.

In eosinophilic colitis group, 30% were smokers whereas 70% were nonsmokers (Fig. 1).

### Statistical methods

The following tests were used:

- (1) Student *t*-test was used for comparison between means of two groups.

**Table 2** Duration of diarrhea in the studied patients

Groups	N	Mean	SD	Minimum	Maximum
NSC	37	11.47	11.40	4	72
MC	5	21.60	28.29	5	72
UC	4	16.25	9.88	7	30
EC	3	10.33	4.04	8	15

EC, eosinophilic colitis; MC, microscopic colitis; NSC, nonspecific colitis; UC, ulcerative colitis.

**Table 3** Drugs consumed in different categories

Drugs	Nonspecific colitis	Microscopic colitis	Ulcerative colitis	Eosinophilic colitis	P value	Significance
No	27 (73%)	0 (0%)	3 (75%)	0 (0%)	0.003	HS
PPI	3 (8%)	4 (80%)	1 (25%)	0 (0%)	0.001	HS
NSAID	3 (8%)	4 (80%)	0 (0%)	1 (33%)	<0.001	HS
Ranitidine	1 (2%)	1 (20%)	0 (0%)	0 (0%)	0.282	NS
Simvastatin	3 (8%)	1 (20%)	0 (0%)	0 (0%)	0.662	NS
Sertaline	0 (0%)	0 (0%)	0 (0%)	0 (0%)	NA	NA

HS, highly significant; NA, not available; PPI, proton pump inhibitor.

- (2) *F*-test (one-way analysis of variance) is a test statistics calculated for comparison between means of three groups.

Fisher's exact test was used to calculate an exact *P* value for a 2×2 frequency table with small number of expected frequencies, for which the  $\chi^2$ -test is not appropriate.

The  $\chi^2$ -test is used to test the statistical significance of differences in a classification system (one-way classification) or the relationship between two classification systems (two-way classification).

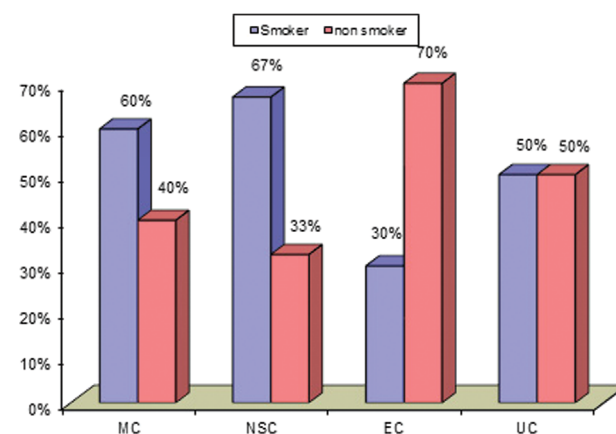
For statistical analysis, statistical package for social science software, version 17 (SPSS Inc., Chicago, Illinois, USA) was used.

### Discussion

Diarrhea-predominant IBS is a widespread GI disorder, but because of the lack of pathognomonic clinical features and specific diagnostic methods, it may be easily misdiagnosed and confused with MC which presents with chronic watery nonbloody diarrhea.

The importance of recognizing this condition is crucial because chronic diarrhea is a debilitating illness and a

**Figure 1**



Smoking status of the studied patients.

proper treatment help a lot of patients to return to normal life [8].

MC is increasingly recognized as a common cause of chronic, nonbloody diarrhea. Epidemiological studies have shown a rising incidence in the last decade. The diagnosis rests on specific histological findings in colonic biopsies from patients with chronic diarrhea demonstrating either LC or CC.

Proper diagnosis and regular follow-ups are important to differentiate these patients from those with IBS, to provide relevant treatment, and to improve quality of life [9].

Colonoscopy with multiple colonic biopsies is the main diagnostic procedure to establish the diagnosis and to rule out other causes of diarrhea.

The key histological feature of LC is an increased proportion of surface intraepithelial lymphocytes. The key histological feature of CC is a broad subepithelial fibrous band of more than 10- $\mu$ m thickness, immediately underneath the surface epithelium [9].

Chromogranin A is a 68-kDa protein comprising 439 amino-acid residues, which was isolated for the first time from secretory granules of the bovine adrenal medulla. Chromogranin A is co-stored and co-released with monoamines and peptide hormones of the adrenal medulla, pituitary gland, parathyroid, thyroid C cells, pancreatic islets, endocrine cells of the GI tract, and sympathetic nerves. Therefore, chromogranin A is considered to be a general marker for all endocrine cells.

The chromogranin cell density seems to be a good diagnostic marker with high sensitivity and specificity in both the right and left colon, thus the diagnosis of LC with the use of this marker [5].

The aim of the current study is to determine the prevalence of MC in cases presented with symptoms of IBS according to Rome IV criteria and to evaluate the role of chromogranin A as a diagnostic marker for cases of MC.

The results of our study showed that of the 50 patients included, there were five (10%) patients of MC (four cases with LC and one case with CC).

In spite of the limited number of cases studied, this percentage is high for the number of the cases studied.

Our results concerning the high prevalence of MC come in accordance with a similar study conducted in Egypt in which the prevalence approached 30% [10].

Another study conducted in Egypt as well also revealed a high prevalence of MC among the studied cases, which approached 50% [11].

The difference in prevalence between the current study and the aforementioned studies might be related to the fact that in the current study all cases that proved to have an organic disease from the history or after obtaining the laboratory and endoscopic results were excluded from the study, and the remaining 50 cases were free from organic disease besides their fulfillment of the Rome IV criteria.

Our results concerning the high prevalence of MC in developing countries come in agreement as well with a study conducted by Valle Mansilla *et al.* [12] in Peru in which it was found that the prevalence of MC was ~40%.

A study that was conducted by Essid *et al.* [13] in Tunis revealed that the prevalence of MCV is 29.3% in patients with chronic diarrhea.

Another study that was conducted in Turkey revealed a prevalence of 4.5% of MC among the studied group of cases [14].

A study that was conducted in Brazil on 184 patients revealed a prevalence of MC at 7% in the studied group [15].

A study conducted in the USA concluded that colonoscopy and colonic mucosal biopsies were able to identify an alternative diagnosis in nine of 466 (1.9%) nonconstipated patients with IBS which raised the concern about the accuracy of Rome III criteria in confirming diagnosis of IBS with diarrhea. Of these nine patients, seven had MC [16].

Taken together, the results of the aforementioned studies, though different in their conclusion regarding the prevalence of MC, have made it clear that MC is not an uncommon disease, and as it can be easily confused with diarrhea-predominant IBS and both conditions have a normal-appearing mucosa during colonoscopic findings, the only way for diagnosing MC is through multiple biopsies taken from the normally appearing mucosa.



In addition, the aforementioned studies showed that the prevalence of LC is more common than CC which comes in agreement with our results (of the five cases of MC, there were four cases of LC and one case of CC).

Regarding sex distribution in our study, of the five patients diagnosed as MC, there were three men (60%) and two women (40%).

Different results were obtained by Olesen and colleagues who revealed high women : men ratio in population diagnosed with MC, where 45/51 were women in CC group and 31/46 were women in the LC group. Moreover, Limsui and colleagues found that 71% of the patients with MC were women.

Similarly, Pardi and colleagues showed that MC was associated with female sex (4.8% women versus 1.1% men in CC and 6.1% women vs. 5% men in LC), and such study was conducted in the USA [3,17,18].

Our results come in accordance with a study conducted by Gado *et al.* [11] who investigated patients with chronic watery diarrhea, where 55% of patients diagnosed with MC were men and 45% women.

Regarding age distribution in our study, age of the patients diagnosed with MC ranged from 21 to 48 years with mean age of 38.8 years in both CC and LC subgroups, and this distribution was near to the results of Gado *et al.* [11].

Our results regarding patients age are close as well with two studies in which the mean age for the studied cases were 45.93 years and ~40 years [19,20].

These results are different from other studies. One of them revealed that the peak incidence for LC and CC was around 65 years, and another study concluded that the mean age was 52.4 years in CC and 55.2 in LC [17,21].

An interesting finding was found in one study in which the authors concluded that MC can occur at any age, and they reported 11 cases in children who were on proton pump inhibitor (PPI) [22].

There was another study that reported the occurrence of MC in pediatric age group [23].

The variability in the peak age for MC might be related to the nonspecificity of the symptoms that can be missed or misdiagnosed as functional bowel disorder.

Regarding the relation of some drugs consumed in cases with MC, there was a highly significant correlation between NSAID and PPI with the documented cases of MC, which might mean a significant role of these drugs in triggering MC.

Our results come in agreement with Beaugierie *et al.* [24] who announced in their review that there are some drugs associated with a high likelihood of inducing MC, which include acarbose, aspirin, lansoprazole, NSAIDs, ranitidine, sertraline, and ticlopidine.

The same conclusions were obtained by Keszthelyi *et al.* [25] who reported that exposure to PPIs at the time of the histological diagnosis was significantly higher in patients with MC than in controls.

In addition, Stoicescu *et al.* [8] showed that MC was associated with nonsteroidal anti-inflammatory drugs in three of 15 patients and lansoprazole in two of 15 patients.

As chromogranin A is a common marker for endocrine cells, the current finding of a high density of colonic chromogranin A cells in patients with LC suggests that colonic hormones are involved in the pathophysiology of LC.

Several studies present solid evidence for the interaction of the gut neuroendocrine peptides/ amines and the local immune system in the gut. This is referred to as the endocrine/immune axis [26].

The results of our study showed that chromogranin A cell density seems to be a good diagnostic marker with a high sensitivity and specificity. This was shown to be true whether biopsies were taken from the right or left colon.

This is in agreement with Yen *et al.* [27] who concluded that by using this marker, biopsies taken from the left colon (sigmoid or descending colon) were enough to make the diagnosis in 98.6% of cases.

Finally, one of the findings of our study is related to correlation of smoking and MC, and in our MC cases, 60% were smokers and 40% nonsmokers, which might indicate more association of smoking with the development of MC.

This is in agreement with Vigren *et al.* [28] who found that of the 116 patients with CC, 37% were smokers

compared with 17% of controls, and the conclusion was smoking is a risk factor for CC.

Another study conducted by Roth *et al.* [29] concluded that that past smoking is associated with transient MC, whereas current smoking is associated with persistent MC. Smoking is associated with patients with MC with concomitant IBS-like symptoms.

In conclusion, MC is not an uncommon disease, and its symptoms resemble those of IBS. Colonoscopy and biopsy are essential tools to rule out the possibility of MC in cases presenting with symptoms of IBS.

Our study to the best of our knowledge is one of the very few studies conducted in Egypt that addressed the prevalence of MC among patients presenting with symptoms of IBS. Moreover, compared with other studies, our study included only those who fulfilled the criteria of IBS according to Rome IV criteria and all other cases that proved to have organic disease were excluded from the study (50 patients from the initial enrolled 100 patients).

However, the results of our study are preliminary and more combined work of multicenter nature needs to be conducted on a wider scale nationwide to determine the actual prevalence of MC in Egypt with long-term follow-up of cases diagnosed as MC to determine the possibility of progressing into inflammatory bowel disease or malignant transformation.

### Acknowledgements

The authors greatly appreciate the tremendous effort done by Dr. Ahmad Riad who was responsible for the preparation of the study subjects.

### Financial support and sponsorship

Nil.

### Conflicts of interest

There are no conflicts of interest.

## References

- 1 Nguyen GC, Smalley WE, Vege SS, Carrasco-Labra A. the Clinical Guidelines Committee. American Gastroenterological Association Institute Guideline on the Medical Management of Microscopic Colitis. *Gastroenterology* 2016; 150:242–246.
- 2 Madisch A, Bethke B, Stolte M, Miehke S. Is there an association of microscopic colitis and irritable bowel syndrome – a subgroup analysis of placebo controlled trials. *World J Gastroenterol* 2005; 11:6409.
- 3 Limsui D, Pardi DS, Camilleri M, Loftus EV Jr, Kammer PP, Tremaine WJ, Sandborn WJ. Symptomatic overlap between irritable bowel syndrome and microscopic colitis. *Inflamm Bowel Dis* 2007; 13:175–181.
- 4 Abboud R, Pardi DS, Tremaine WJ, Kammer PP, Sandborn WJ, Loftus EV Jr. Symptomatic overlap between microscopic colitis and irritable bowel syndrome: a prospective study. *Inflamm Bowel Dis* 2013; 19:550–553.
- 5 El-Salhy M, Gundersen D, Hatlebakk JG, Hausken T. Chromogranin A cell density as a diagnostic marker for lymphocytic colitis. *Dig Dis Sci* 2012; 57:3154–3159.
- 6 Lacy BE, Mearin F, Chang L, Chey WD, Lembo AJ, Simren M, Spiller R. Bowel disorders. *Gastroenterology* 2016; 150:1393–1407.
- 7 Pardi DS, Smyrk TC, Tremaine WJ, Sandborn WJ. Microscopic colitis: a review. *Am J Gastroenterol* 2002; 97:794–802.
- 8 Stoicescu A, Becheanu G, Dumbrava M, Gheorghe C, Diculescu M. Microscopic colitis – a missed diagnosis in diarrhea-predominant irritable bowel syndrome. *Maedica (Buchar)* 2012; 7:3–9.
- 9 Münch A, Aust D, Bohr J, Bonderup O, Fernández Bañares F, Hjortswang H, *et al.* for the European Microscopic Colitis Group. (EMCG) Microscopic colitis: current status, present and future challenges. *J Crohn's Colitis* 2012; 6:932–945.
- 10 Ramadan Abdelhai A, Fattah S, Ismail WA, El-Kashishy KA. The yield of mapping biopsy from apparent endoscopically normal colon and correlation with symptoms. *J Gastroenterol Hepatol Res* 2014; 3:1168–1172.
- 11 Gado AS, Ebeid BA, El Hindawi AAz, Akl MM, Anthony T. Axon prevalence of microscopic colitis in patients with chronic diarrhea in egypt: a single-center study. *Saudi J Gastroenterol* 2011; 17:383–386.
- 12 Valle Mansilla JL, León Barúa R, Recavarren Arce S, Berendsen Seminario R, Biber Poillevard M. Microscopic colitis in patients with chronic diarrhea. *Rev Gastroenterol Peru* 2002; 22:275–278.
- 13 Essid M, Kallel S, Ben Brahim E, Chatti S, Azzouz MM. Prevalence of the microscopic colitis to the course of the chronic diarrhea: about 150 cases. *Tunis Med* 2005; 83:284–287.
- 14 Ozdil K, Sahin A, Calhan T, Kahraman R, Nigdelioglu A, Akyuz U, Sokmen HM. The frequency of microscopic and focal active colitis in patients with irritable bowel syndrome. *BMC Gastroenterol* 2011; 11:96.
- 15 Magro F, Langner C, Driessen A, Ensari A, Geboes K, Mantzaris GJ, *et al.* European consensus on the histopathology of inflammatory bowel disease. *J Crohns Colitis* 2013; 7:827–851.
- 16 Chey WD, Nojkov B, Rubenstein JH, Dobhan RR, Greenston JK, Cash BD. The yield of colonoscopy in patients with non-constipated irritable bowel syndrome: results from a prospective, controlled US trial. *Am J Gastroenterol* 2010; 105:859–865.
- 17 Olesen M, Eriksson S, Bohr J, Järnerot G, Tysk C. Microscopic colitis: a common diarrhoeal disease. An epidemiological study in Örebro, Sweden, 1993–1998. *Gut* 2004; 53:346–350.
- 18 Pardi DS, Loftus EV Jr, Smyrk TC, Kammer PP, Tremaine WJ, Schleck CD, *et al.* The epidemiology of microscopic colitis: a population based study in Olmsted County, Minnesota. *Gut*. 2007; 56:504–508.
- 19 Tavakkoli H, Esmaeili FS, Emami MH, Mahzouni P, Haghdani S. Is microscopic colitis a missed diagnosis in diarrhea-predominant irritable bowel syndrome? *JRMS* 2008; 13:202–206.
- 20 Calabrese C, Gionchetti P, Liguori G, Areni A, Fornarini GS, Campieri M, Rizzello F. Clinical course of microscopic colitis in a single center cohort study. *J Crohns Colitis* 2011; 5:218–221.
- 21 Misra V, Misra SP, Dwivedi M, Singh PA, Agarwal V. Microscopic colitis in patients presenting with chronic diarrhea. *Indian J Pathol Microbiol* 2010; 53:15–19.
- 22 El-Matary W, Girgis S, Huynh H, Turner J, Diederichs B. Microscopic colitis in children. *Dig Dis Sci* 2010; 55:1996–2001.
- 23 Singh P, Das P, Jain AK, Mathan M, Mathur M, Bhat AS, *et al.* Microscopic colitis in children with chronic diarrhea. *J Pediatr Gastroenterol Nutr* 2013; 57:240–244.
- 24 Beaugerie L, Pardi DS. Review article: drug-induced microscopic colitis – proposal for a scoring system and review of the literature. *Aliment Pharmacol Ther* 2005; 22:277–284.
- 25 Keszthelyi D, Jansen SV, Schouten GA, de Kort S, Scholtes B, Engels LG, Masclee AA. Proton pump inhibitor use is associated with an increased risk for microscopic colitis: a case-control study. *Aliment Pharmacol Ther* 2010; 32:1124–1128.
- 26 Khan WI, Ghia JE. Gut hormones: emerging role in immune activation and inflammation. *Clin Exp Immunol* 2010; 161:19–27.
- 27 Yen EF, Pardi DS. Review article: microscopic colitis-lymphocytic, collagenous and 'mast cell' colitis. *Aliment Pharmacol Ther* 2011; 34:21–32.
- 28 Vigren L, Sjöberg K, Benoni C, Tysk C, Bohr J, Kilander A, *et al.* Is smoking a risk factor for collagenous colitis? *Scand J Gastroenterol* 2011; 46:1334–1339.
- 29 Roth B, Gustafsson RJ, Jeppsson B, Manjer J, Ohlsson B. Smoking and alcohol habits in relation to the clinical picture of women with microscopic colitis compared to controls. *BMC Womens Health* 2014; 14:16.