

# Case study and review article: epilepsy-like movements induced by fentanyl analgesia

Mahmoud El-Karamany

Department of Gastroenterology, Hull and East Yorkshire Hospitals NHS Trust, Hull, UK

Correspondence to Mahmoud El-Karamany, MRCPI, MD, Department of Gastroenterology, Hull and East Yorkshire Hospitals NHS Trust, UK, Anlaby Road, Hull HU3 2JZ, UK; Tel: 07840469910; fax: 01904211065; e-mail: mahmoud.elkaramany@hey.nhs.uk

Received 3 April 2017

Accepted 2 May 2017

The Egyptian Journal of Internal Medicine  
2017, 29:86–90

Epilepsy-like movements are observed immediately after the administration of fentanyl as well as its derivatives. Although the event has no serious outcomes, it is so worrisome that it has garnered the attention of many authors to publish case reports of such events. Despite the presence of cerebral lesions in some cases, epileptic focus cannot be attributed to such lesions. Radiological and electrophysiological studies have failed to reveal abnormal cerebral activity during such events. The reported activity is usually generalized tonic–clonic convulsions. Epileptic convulsive movements were observed with low doses of fentanyl and its derivatives. Previous studies on animals have supported the occurrence of such epileptiform movements in corresponding doses. Idiosyncrasy and narcotic-related muscle rigidity did not satisfactorily explain the seizures. Our case report represents the occurrence of epileptiform movements twice in an old patient with no cerebral insult. The past history was epileptic activity under control with lamotrigine for last 2 years.

## Keywords:

analgesics, convulsions, epilepsy, fentanyl, seizures

Egypt J Intern Med 29:86–90

© 2017 The Egyptian Journal of Internal Medicine  
1110-7782

## Fentanyl analgesia

It has been noticed that administration of fentanyl during anesthesia is accompanied by epilepsy-like movements. Evaluation of brain activity using conventional electroencephalogram (EEG) showed no epileptic activity or focal epileptic wave changes. These findings cast on the nature, and hence the diagnosis of these observed abnormal movements.

Epilepsy is not a well-known side-effect of fentanyl. There are only observations of abnormal muscle contractions that are interpreted as convulsions [1]. However, EEG performed during such episodes show normal tracing [2].

Case reports are the only available data sources on epilepsy-like events that start a few minutes after administration of fentanyl or its analogs [3].

## Case report

### Subjective data

We report the case of a 71-year-old man weighing 80 kg. He had a past history of angina pectoris for 20 years and was maintained on nifedipine, metoprolol, and transdermal nitroglycerine. The patient has Epilepsy for 14 years before and currently on Lamotrigine 150 mg a day is correct. No permanent neurological deficit ensued. No history of any epileptic activity during the past 2 years was reported or documented. The patient was referred for elective gastroscopy and

colonoscopy for investigation of mild anemia (hemoglobin 11.3 g/dl, ferritin 15, mean corpuscular volume 71).

### Anesthetic events

The patient was assessed and found to have normal blood pressure of 124/86, O<sub>2</sub> saturation of 98% on room air, and his heart rate was 84 beats/min. He provided formal consent for the procedure. Fentanyl 50 mg intravenously was administered, and the patient developed tremulous movements in the left hand immediately, followed by the left arm and left foot. Subsequently, all four limbs were involved in grand mal seizure with tonic–clonic contractions. The patient was given 2 mg of midazolam intravenously, and the seizure stopped. During that episode, the patient was vitally stable. He was admitted to the recovery room for observation before discharge.

A computed tomographic scan of the head was performed 2 weeks later and the results were normal.

### Learning point

We can avoid using fentanyl as a sedative in epileptic patients, or it can be administered at lower doses with extreme caution.

This is an open access article distributed under the terms of the Creative Commons Attribution-NonCommercial-ShareAlike 3.0 License, which allows others to remix, tweak, and build upon the work noncommercially, as long as the author is credited and the new creations are licensed under the identical terms.

## Fentanyl: drug information

### Pharmacological aspects of fentanyl

#### Clinical pharmacology

Fentanyl belongs to the family of anilidopiperidine opioids used for general anesthesia. Fentanyl exerts its analgesic action by binding to stereospecific receptors leading to increased pain threshold, depression of ascending pain pathways, and changes in reception of pain.  $\mu$ -Opiate receptors that are located in the periphery mediate the analgesic effects of fentanyl as well as respiratory depression [4].

It is a good practice to titrate the dose of fentanyl to alleviate and/or prevent pain with monitoring of vital signs. During surgery, fentanyl is usually administered at a dose of 50–100 mcg by intramuscular or slow intravenous route in 30–60 min before surgery or 25–50 mcg by slow intravenous soon before induction [5]. Doses and dosage interval vary according to the severity of pain [6] and the critical condition of the patient [7]. Fentanyl can also be given to children aged more than 2 years and adolescents, as an adjunct to anesthesia [8], at a dose of 2–3 mcg/kg/dose by intravenous route, to be repeated every 1–2 h when appropriate. No dose adjustment is needed in patients with renal or hepatic impairment [1].

Fentanyl is used to relieve preoperative and postoperative pain, adjunct to general or regional anesthesia, acute or chronic pain, and cancer pain. It is worth mentioning that the Benzodiazepines and Opioid Medicine Safety

Alert August 2016 focused on the combination of opioid medications with benzodiazepines or other central nervous system depressants. Respiratory compromise and death are the most serious adverse effects of such combinations [9]. Other adverse effect worth attention are listed collectively in Table 1 [4].

#### Pharmacodynamics and pharmacokinetics

The onset of action varies with age and route of administration. Children aged 3–12 years show the effects of fentanyl in 5–10 min by the intranasal route. Fentanyl administration in adults by intramuscular route takes about 8 min to exert full effect and it is immediate by intravenous route. A transdermal patch takes 6 h, and the transmucosal route takes 5–15 min to exert the full effect of fentanyl.

The duration of fentanyl effect is 1–2 h by intramuscular route and 0.5–1 h by intravenous route. The duration reaches up to 96 h through the transdermal route and even longer by the transmucosal route.

Fentanyl absorption varies with the route of administration. The drug is released from the transdermal patch and accumulates in the outer layers of the skin, from which the drug is released into the circulation, leading to constant circulating levels for 12–24 h. Transdermal devices release fentanyl within 10 min, and the amount of drug in blood keeps increasing for about 5 min after that. Nearly 50% of buccal tablets and films are rapidly absorbed from the buccal mucosa, and the remaining

**Table 1 The side-effects of fentanyl according to significance**

System affected	>10%	1–10%
Central nervous	Confusion, dizziness, drowsiness, fatigue, headache, sedation.	Abnormal gait, abnormal dreams, agitation, amnesia, ataxia, depression, hypoesthesia, hypothermia, paranoia, speech disturbance
Cardiovascular	–	Atrial fibrillation, arrhythmia, chest pain, deep vein thrombosis, myocardial infarction, orthostatic hypotension, pulmonary embolism, syncope
Gastrointestinal	Constipation, nausea, vomiting	Distention, pain, anorexia, diarrhea, dysphagia, ulcer, stomatitis, periodontal abscess
Endocrine	Dehydration	Hot flash, hypercalcemia, hyperglycemia, hypoalbuminemia, hypokalemia, hypomagnesemia
Musculoskeletal	Weakness	–
Respiratory	Dyspnea	Apnea, asthma, atelectasis, bronchitis, cough, dyspnea, epistaxis, hemoptysis, pneumonia, sinusitis
Skin	–	Alopecia, cellulitis, decubitus ulcer, diaphoresis, erythema, skin rash, vesicobullous rash
Genitourinary	–	Retention, dysuria, erectile dysfunction, mastalgia, incontinence, infection, urgency, bleeding, vaginitis
Hematologic and oncologic	–	Anemia, leukopenia, lymphadenopathy, neutropenia
Hepatic	–	Ascites, high serum alkaline phosphatase, high level of aspartate aminotransferase, jaundice
Renal	–	Renal failure
Local	–	Burning sensation at the applicant site, discharge, edema, pain, vesicles

is swallowed and absorbed from gut. Lozenges has about 25% absorption from the buccal mucosa, and the rest is absorbed from gut.

Fentanyl is highly lipophilic. It shows a three-compartment distribution mode affected by blood pH.  $V_{dss}$  ranges from 5 to 30 l/kg in children and from 4 to 6 l/kg in adults. Fentanyl binds to  $\alpha$ -1 acid glycoprotein, albumin, and erythrocytes (79–87%).

It is metabolized in the liver by CYP3A4 by *N*-dealkylation into inactive metabolites: norfentanyl and hydroxylated compounds.

The buccal film has 40% exposure systemically (area under the curve), which is higher compared with transmucosal lozenge. The bioavailability of buccal tablets is 65%, lozenge 50%, sublingual spray 76%, and sublingual tablet 54%.

The half-life of fentanyl varies by age (Table 2). The normal range is 2–4 h; however, it increases with continuous infusion because of its large volume of distribution [10].

Fentanyl is excreted in urine mostly as inactive metabolites (75%) and in its native form (7–10%). Excretion through feces is around 9%. Fentanyl clearance in newborn infants is related to gestational age and birth weight [11].

## Discussion

Many studies have been continuously reporting epilepsy-like movements and muscle activity related to fentanyl administration. Safwat *et al.* [12] reported on the occurrence of grand mal epilepsy in a 71-year-old woman, who was scheduled for hysterectomy, after administration of 200  $\mu$ g fentanyl. Brian and Seifen [13] observed tonic-clonic activity in a 69-year-old man, who was scheduled for coronary artery bypass

grafting operation, after administering 58  $\mu$ g of sufentanil. A recent study by Haber and Litman [14] reported generalized tonic-clonic convulsive episodes associated with loss of consciousness in a 42-year-old woman scheduled for hysteroscopy and polypectomy, after using remifentanyl, a fentanyl analog, at a dose of 10  $\mu$ g/kg/min by continuous infusion. Moreover, administering fentanyl in young children has the same effect as in adults. Hsieh *et al.* [15] reported the occurrence of generalized tonic-clonic convulsions in a 10-year-old girl scheduled for elective tenectomy, after receiving fentanyl and lidocaine. EEG tracing during the epileptiform activity showed no significant abnormality (Fig. 1) [3,16]. Epilepsy occurs with low doses of narcotic anesthesia ranging from 44 to 78.1  $\mu$ g/kg for fentanyl [17] and 0.7  $\mu$ g/kg for sufentanil [13]. Doses as low as 100  $\mu$ g of fentanyl can induce grand mal epilepsy in patients with previous neurological deficits [15]. In agreement with most of the previously reported cases, our case showed no epileptic seizures for 2 years or neurological abnormalities.

Thorough clinical history taking and review of medical records fail to show the occurrence of epilepsy in otherwise healthy individuals. Most events of epilepsy related to fentanyl or its analogs were accidentally discovered and managed accordingly by postponing surgery. This case report of a 71-year-old man with past history of healed cerebral infarct is one example of many such cases [3].

A long-term, retrospective, matched cohort study showed that the initial therapy for epilepsy with enzyme-induced antiepileptic drugs (EIAED) causes a serious impact on patient health compared with non-EAAED [18].

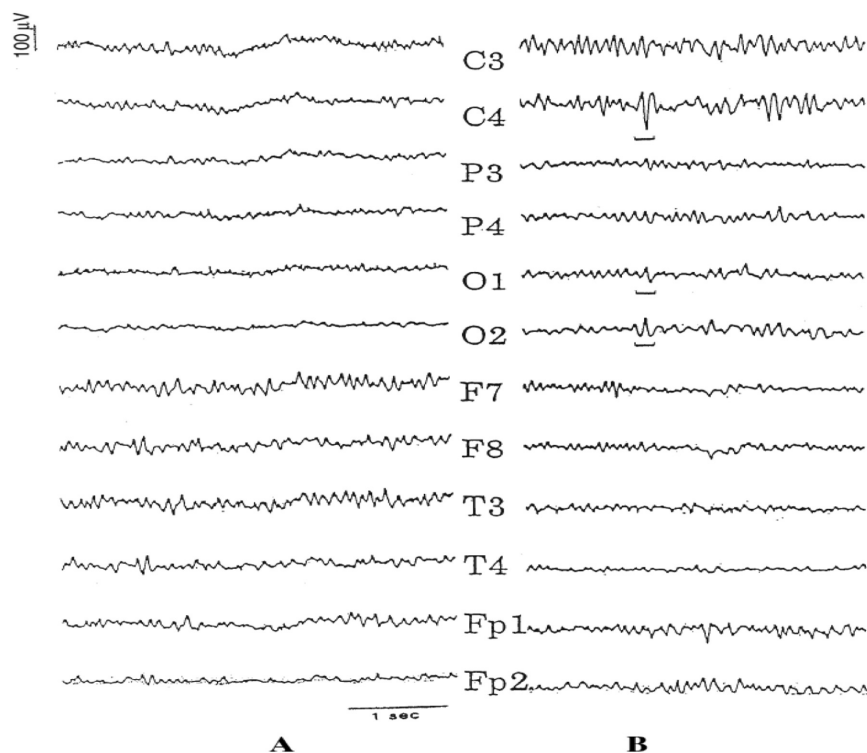
Other explanations have been provided by Scott and Sarnquist [19]. The first suggestion presumed an exaggeration of narcotic-induced muscle rigidity,

**Table 2 Fentanyl half-life and time to peak levels**

Route of administration	Age	Half-life (h)	Time to peak
Intravenous	5 months–4.5 years Adults	2.4 2–4	Immediate
Intravenous infusion	6 months–14 years	11–36	Immediate
Transdermal device	–	16	–
transdermal patch	–	20–27	20–72 h
transmucosal products	–	3–14	Sublingual spray: 90 min Sublingual tablet: 15–240 min
Nasal spray	–	15–14	15–21 min
Buccal film	–	14	0.75–4 h
Buccal tablet	–	3–4 <sup>a</sup>	20–240 min

<sup>a</sup>Buccal tablet: 100–200 mcg.

Figure 1



The electroencephalogram (EEG) tracing of the 79-year-old man, weighing 54 kg, who was scheduled for elective laminoplasty at the level of C3–C7. (a) EEG 1 year preoperatively showing normal  $\beta$  wave tracing. (b). EEG during fentanyl induction showing  $\alpha$  waves.

whereas the second suggestion was about a kind of myoclonus secondary to inhibitory neuronal depression induced by narcotics. However, the first suggestion can be ruled out by the observation that the patient received 2 mg of vecuronium, which inhibits narcotic rigidity and ventilation can be easily provided through a mask. Therefore, it lacks evidence for muscle rigidity. The duration of the seizure cannot be estimated in our case because of the paralyzing effect of using 8 mg vecuronium. The second suggestion is strongly related to our case report. Myoclonic activity [20] is highly related to narcotic anesthesia [21]. In contrast to epileptic seizure, myoclonic movements are related to either rhythmic or arrhythmic contractions of the muscles. Findings on EEG determine whether the myoclonus activity is epileptic or nonepileptic [22].

Fentanyl is one of the drugs whose concentrations can be decreased by co-administration with EIAED (carbamazepine, phenobarbital, phenytoin, and primidone) [23] and lamotrigine is not an exception [24]. Lamotrigine's side-effect that enforces cessation of the drug is rash. The most commonly reported side-effects of lamotrigine were dizziness, nausea, and somnolence. Epilepsy has not been mentioned frequently, however [25]. Lamotrigine has not been mentioned as having negative drug interactions or is not contraindicated for administration along with

fentanyl; even epilepsy is not proved to be one of the documented side-effect of fentanyl and its analogs [26]. Both lamotrigine and fentanyl have similar impact on the brain. However, no evidence-based study has revealed that such an impact is synchronized or augmented. Further studies are needed in this field to document observations and side-effects.

#### Financial support and sponsorship

Nil.

#### Conflicts of interest

There are no conflicts of interest.

#### References

- Bowdle T, Rooke G. Postoperative myoclonus and rigidity after anesthesia with opioids. *Anesth Analg* 1994; 78:783–786.
- Hsieh X, Hsu Y, Cherng C, Lin C, Huang G, Lin S, *et al.* Grand mal seizure induced by low-dose fentanyl and lidocaine in a young child. *Acta Anaesthesiol Taiwan* 2015; 53:105–108.
- Katz R, Eide T, Hartman A, Poppers P. Two instances of seizure-like activity in the same patient associated with two different narcotics. *Anesth Analg* 1988; 67:289–290.
- Henderson F, May W, Gruber DJ, Puskovic Y, Young A. Role of central and peripheral opiate receptors in the effects of fentanyl on analgesia, ventilation and arterial blood-gas chemistry in conscious rats. *Respir Physiol Neurobiol* 2014; 191:95–105.
- Barash P, Cullen B, Stoelting R. *Clinical anesthesia*. 6th ed. Philadelphia, PA: Lippincott Williams & Wilkins; 2009.
- Barr J, Fraser G, Gilles L, Puntillo K, Ely W, Gélinas C, *et al.* Clinical practice guidelines for the management of pain, agitation, and delirium in adult patients in the intensive care unit. *Crit Care Med* 2013; 41:263–306.

- 7 Liu L, Gropper M. Postoperative analgesia and sedation in the adult intensive care unit. *Drugs* 2003; 63:755–767.
- 8 Medscape. Sublimaze (fentanyl) dosing, indications, interactions, adverse effects, and more; 2016. Available at: <http://reference.medscape.com/drug/sublimaze-fentanyl-343311#0>. [Accessed 31 October 2016].
- 9 US Food and Drug Administration. Opioid pain or cough medicines combined with benzodiazepines: drug safety communication – FDA requiring boxed warning about serious risks and death; 2016. Available at: [http://www.fda.gov/Safety/MedWatch/SafetyInformation/SafetyAlertsforHumanMedicalProducts/ucm518710.htm?source=govdelivery&utm\\_medium=email&utm\\_source=govdelivery](http://www.fda.gov/Safety/MedWatch/SafetyInformation/SafetyAlertsforHumanMedicalProducts/ucm518710.htm?source=govdelivery&utm_medium=email&utm_source=govdelivery). [Accessed 31 October 2016].
- 10 Sessler C, Varney K. Patient-focused sedation and analgesia in the ICU. *Chest* 2008; 133:552–565.
- 11 Saarenmaa E, Neuvonen P, Fellman V. Gestational age and birth weight effects on plasma clearance of fentanyl in newborn infants. *J Pediatr* 2000; 136:0767–0770.
- 12 Safwat A, Daniel D. Grand mal seizure after fentanyl administration. *Anesthesiology* 1983; 59:78.
- 13 Brian J, Seifen A. Tonic-clonic activity after sufentanil. *Anesth Analg* 1987; 66:481.
- 14 Haber G, Litman R. Generalized tonic-clonic activity after remifentanyl administration. *Anesth Analg* 2001; 93:1532–1533.
- 15 Hsieh X, Hsu Y, Cherng C, Lin C, Huang G, Lin S. Grand mal seizure induced by low-dose fentanyl and lidocaine in a young child. *Acta Anaesthesiol Taiwan* 2015; 53:105–108.
- 16 Scott JF. Seizure-like movements during a fentanyl infusion with absence of seizure activity in a simultaneous EEG recording. *Anesthesiology* 1985; 62:812–813.
- 17 Fujimoto T, Nishiyama T, Hanaoka K. Seizure induced by a small dose of fentanyl. *J Anesth* 2003; 17:55–56.
- 18 Borghs S, Thieffry S, Noack-Rink M, Dedeken P, Hong L, Byram L, *et al*. Health care cost associated with the use of enzyme-inducing and non-enzyme-active antiepileptic drugs in the UK: a long-term retrospective matched cohort study. *BMC Neurol* 2017; 17:1.
- 19 Scott J, Sarnquist F. Seizure-like movements during a fentanyl infusion with absence of seizure activity in a simultaneous EEG recording. *Anesthesiology* 1985; 62:812–813.
- 20 Larson K, Wittwer E, Nicholson W, Weingarten T, Price D, Sprung J. Myoclonus in patient on fluoxetine after receiving fentanyl and low-dose methylene blue during sentinel lymph node biopsy. *J Clin Anesth* 2015; 27:247–251.
- 21 Richardson S, Egan T. The safety of remifentanyl by bolus injection. *Expert Opin Drug Saf* 2005; 4:643–651.
- 22 Modica P, Tempelhoff R, White P. Pro- and anticonvulsant effects of anesthetics (part I). *Anesth Analg* 1990; 70:303–315.
- 23 Patsalos P, Perucca E. Clinically important drug interactions in epilepsy: interactions between antiepileptic drugs and other drugs. *Lancet Neurol* 2003; 2:473–481.
- 24 Perucca E. Clinically relevant drug interactions with antiepileptic drugs. *Br J Clin Pharmacol* 2006; 61:246–255.
- 25 Szaflarski J, Linda Steinbaugh MD. Adjunctive therapy for the treatment of primary generalized tonic-clonic seizures: focus on once-daily lamotrigine. *Drug Des Devel Ther* 2010; 4:337–342.
- 26 Medscape. Sublimaze (fentanyl) dosing, indications, interactions, adverse effects, and more; 2017. Available at: <http://reference.medscape.com/drug/sublimaze-fentanyl-343311#4>. [Last accessed 2010].