

Hodgkin's lymphoma presenting as autoimmune hemolytic anemia

Sohaila Fatima^a, Wajih A. Siddiqui^b, Abdulrahman Alshehri^b

^aDepartment of Pathology, King Khalid University, ^bHemato-Oncology Unit, Department of Internal Medicine, Aseer Central Hospital, Abha, Saudi Arabia

Correspondence to Sohaila Fatima, MBBS, MD, Alsamir Girls Center, King Khalid University, Abha, 61421, Saudi Arabia; Mobile: 00966-502184094; e-mails: sohailafatima@gmail.com

Received 30 March 2017

Accepted 26 July 2017

The Egyptian Journal of Internal Medicine 2017, 29:144–146

Hodgkin's lymphoma is a B-cell neoplasm, which usually presents with painless lymphadenopathy. Its presentation with autoimmune hemolytic anemia (AIHA) is rare, although the association of AIHA with other lymphoproliferative disorders is well known. Here, we report a case of a patient with warm AIHA who presented in a critical condition to hospital and was diagnosed with HL.

Keywords:

autoimmune hemolytic anemia, Hodgkin's, lymphoma, presentation

Egypt J Intern Med 29:144–146

© 2017 The Egyptian Journal of Internal Medicine 1110-7782

Introduction

Autoimmune hemolytic anemia (AIHA) has a known association with lymphoproliferative disorders but is rarely the presentation of Hodgkin's lymphoma (HL). AIHA is an acquired clinical condition and is characterized by the production of autoantibodies that bind to the surface of circulating erythrocytes leading to hemolysis and decreased survival of the red blood cells [1]. HL is a monoclonal B-cell neoplasm presenting typically with painless lymph nodes or less commonly with extranodal localizations. In this report, we describe the case of a patient with HL who presented in a critical condition with warm antibody type autoimmune hemolytic anemia (wAIHA).

Case report

A 26-year-old man presented with the history of upper respiratory tract infection, fever, shortness of breath, and fatigability of 2 weeks' duration. Clinical examination revealed marked pallor with moderate jaundice associated with multiple palpable left cervical lymph nodes, largest being 2×1 cm. There was splenomegaly and no edema of the extremities. A complete blood count showed macrocytic anemia with hemoglobin of 3.7 g/dl and mean corpuscular volume of 108 fl, white blood cells of $5.8 \times 10^3/\mu\text{l}$, platelets of $357 \times 10^3/\mu\text{l}$, and reticulocyte count of 23%. Direct antiglobulin test at 37°C was strongly positive (3+) for IgG and C3d. Bilirubin was raised at 3.3 $\mu\text{mol/l}$ with elevated indirect bilirubin of 2.9 $\mu\text{mol/l}$ and lactate dehydrogenase of 222 U/l. He was diagnosed as wAIHA and was started on 10 mg/day dexamethasone, which was gradually tapered, and least incompatible packed red cell transfusions. Subsequently, the patient underwent lymph node biopsy, which revealed HL classic type lymphocyte

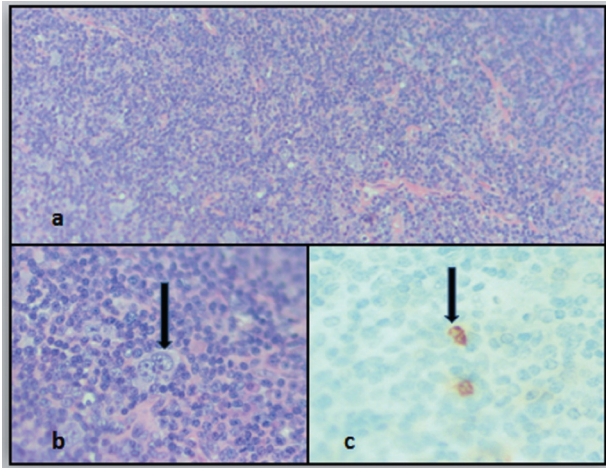
rich with large mononuclear cells being positive for CD30, CD20, and Epstein-Barr virus (EBV) (Fig. 1). A whole-body computed tomography scan showed cervical and mediastinal lymphadenopathy, tiny pleural-based nodules, and hepatosplenomegaly. A diagnosis of wAIHA associated with HL was made. Currently he is receiving chemotherapy with the regimen doxorubicin, bleomycin, vinblastine, and dacarbazine (ABVD): rituximab 375 mg/m², doxorubicin 25 mg/m², bleomycin 10 U/m², vinblastine 6 mg/m², and dacarbazine 375 mg/m².

Discussion

The estimated incidence of AIHA in adults is 0.8–3/100 000 per year with a mortality rate of 11% [2]. AIHA caused by wAIHA accounts for 70–80% of all cases in adults and for almost 90% of the cases in children. It can be either primary (idiopathic) or secondary associated with an underlying disease (lymphoproliferative disorder, 20%; autoimmune disease, 20%; infections and tumors) [3]. AIHA may occur in lymphoproliferative diseases, especially chronic lymphocytic leukemia (5–10%) and non-HL (2–3%) but is rarely seen in HL [4]. The association of AIHA and HL was first described by Bowdler and Glick [5]. HL arises from germinal center or postgerminal center B-cells. It has a unique cellular composition containing a minority of neoplastic cells (Reed–Sternberg cells and their variants) in an inflammatory background. It can be divided into two major subgroups, based on the appearance and immunophenotype of the tumor cells: (a) nodular

This is an open access article distributed under the terms of the Creative Commons Attribution-NonCommercial-ShareAlike 3.0 License, which allows others to remix, tweak, and build upon the work noncommercially, as long as the author is credited and the new creations are licensed under the identical terms.

Figure 1



(a) Loss of architecture of lymph node with predominance of lymphocytes, macrophages and large atypical mononuclear cells. (Haematoxylin and eosin x10). (b) A large RS like cell seen in a background of lymphocytes (HEx 40). (c) Immunohistochemistry showing CD30 positivity in atypical mononuclear cells

lymphocyte-predominant HL, and (b) classical HL. The tumor cells in the classical HL group are derived from germinal center B-cells and are further divided into the following subtypes: (i) nodular sclerosis HL (NSHL); (ii) mixed cellularity HL (MCHL); (iii) lymphocyte-rich HL (LRHL); and (iv) lymphocyte-depleted HL (LDHL) [6]. The incidence of patients diagnosed with AIHA and HL follows the incidence trend of HL in the general population with a male predominance, but there is an increased prevalence in those under 20 years of age. Among 29 cases with reported pathologic subtypes, 48% had MCHL, 34% had NSHL, 10% had LRHL, 3% had both MCHL and NSHL, and 3% fell between NSHL and LDHL. AIHA was the onset symptom of HL in 40% patients, but it preceded HL by 8–36 months in 20% of patients [7]. The neoplastic cells stain positively for CD30, CD15, and B-cell-specific activating protein, which is the product of the *PAX5* gene. CD20 marker of B-cell lineage is positive in about 40% of cases of classic HL. In contrast, nodular lymphocyte-predominant HL almost always stains strongly positive for CD20 and for the specialized B-cell markers CD79a and CD45, but it is negative for CD30 and CD15 [6]. Our patient was a 26-year-old male who was diagnosed as LRHL, which was positive for CD30, CD20, and EBV but negative for CD3 and CD21. The pathogenic mechanisms leading to the development of HL include both environmental and genetic factors, with a strong association with EBV coinfection and human leukocyte antigen genotypes I and III [8]. One EBV gene expressed at very high levels in HL. LMP2A (membrane protein) carries an immunoreceptor tyrosine-based

activation motif, which resembles that carried by immunoglobulin molecules. When expressed at the cell membrane LMP2A provides a tonic signal that inhibits apoptosis [9]. The pathogenesis of autoimmune symptoms in HL remains unclear. However, multiple processes lead to the formation of autoantibodies in patients with B-cell or T-cell non-HL. Failure of immune tolerance mechanisms to eliminate immature lymphocytes that have been exposed to certain antigenic determinants on the surface of red blood cells, platelets, and clotting factors may lead to the generation of selected clones of autoreactive lymphocytes. These cells may either be deleted from the immune repertoire through intact apoptotic mechanism or remain dormant in peripheral lymphoid compartments. Subsequently the autoreactive clone may be reactive because of new genetic abnormalities or systemic viral infections or because of unknown events. Defects in the apoptotic pathways such as FAS/Fas L and others may lead to an excessive accumulation of a T-cell clone. A neoplastic T-cell may promote antibody production by B-cell through negative signaling or excessive cytokine release. Similarly certain genetic events and abnormalities in the interaction between B and T cells may result in the generation of a malignant B-cell-producing antibody or a malignant B-cell and a nonmalignant B-cell-producing antibody [10].

The traditional treatment of wAIHA is the use of corticosteroid as first-line therapy and conventional immunosuppressive drugs or surgical splenectomy as second-line therapy. New therapeutic approaches such as rituximab (anti-CD20 monoclonal antibody), erythropoiesis-stimulating agents, other immunosuppressive agents such as cyclosporine A, mycophenolate mofetil, and danazol (synthetic anabolic steroid) have become available [2]. Patients with early-stage HL are treated with combined modality strategies utilizing abbreviated courses of combination chemotherapy followed by involved-field radiation therapy, whereas those with advanced stage disease receive a longer course of chemotherapy often without radiation therapy. The most common and effective regimen is ABVD. Rituximab has been added to ABVD chemotherapy to deplete intratumoral B-cells that may support the growth and survival of the malignant cells leading to high complete response rates and the event-free survival [11].

Conclusion

Autoimmune manifestations such as AIHA can precede the diagnosis of HL sometimes by an extensive period of time. Therefore, these diagnoses

should be excluded in persons presenting with AIHA without an obvious cause.

Financial support and sponsorship

Nil.

Conflicts of interest

There are no conflicts of interest.

References

- 1 Lanzkowsky P, editor. Manual of pediatrics hematology and oncology. 5th ed. New York, NY, USA: Elsevier; 2011.
- 2 Zanella A, Barcellini W. Treatment of autoimmune hemolytic anemias. *Haematologica* 2014; 99:1547–1554.
- 3 Michel M. Warm autoimmune hemolytic anemia: advances in pathophysiology and treatment. *Presse Med* 2014; 43(Pt 2):e97–e104.
- 4 Sokol RJ, Booker DJ, Stamps R. Erythrocyte autoantibodies, autoimmune haemolysis, and carcinoma. *J Clin Pathol* 1994; 47:340–343.
- 5 Bowdler AJ, Glick IW. Autoimmune hemolytic anaemia as the herald case of Hodgkin's disease. *Ann Intern Med* 1966; 65:671–677.
- 6 Swerdlow SH, Campo E, Harris NL, Jaffe ES, Pileri SA, Stein H, *et al.* WHO classification of tumours of haematopoietic and lymphoid tissues. In: Bosman FT, Jaffe ES, Lakhani SR, Ohgaki H, editors. World Health Organization Classification of Tumours. Lyon, France: IARC; 2008.
- 7 Feng Q, Zak D, Daya R. Autoimmune hemolytic anemia and classical Hodgkin lymphoma: a case report and literature review. *Clin Adv Hematol Oncol* 2012; 10:270–276.
- 8 Farrell K, Jarrett RF. The molecular pathogenesis of Hodgkin lymphoma. *Histopathology* 2011; 58:15–25.
- 9 Portis T, Dyck P, Longnecker R. Epstein-Barr virus (EBV) LMP2A induces alterations in gene transcription similar to those observed in Reed-Sternberg cells of Hodgkin lymphoma. *Blood* 2003; 102: 4166–4178.
- 10 Sallah S, Sigounas G, Vos P, Wan JY, Nguyen NP. Autoimmune hemolytic anemia in patients with non-Hodgkin's lymphoma: characteristics and significance. *Ann Oncol* 2000; 11:1571–1577.
- 11 Ansell SM. Hodgkin lymphoma: 2016 update on diagnosis, risk-stratification, and management. *Am J Hematol* 2016; 91:434–442.