

# Pulmonary function test in upper airway obstruction: a simple yet effective diagnostic test

Amit Panjwani<sup>a,b,c</sup>, Jaini Lodha<sup>d</sup>

<sup>a</sup>Department of Pulmonary Medicine, Salmaniya Medical Complex, Manama, <sup>b</sup>Royal College of Surgeons, Ireland Medical University of Bahrain, Busaiteen, Kingdom of Bahrain, Departments of <sup>c</sup>Pulmonary Medicine, <sup>d</sup>Otorhinolaryngology, Seven Hills Hospital, Mumbai, Maharashtra, India

Correspondence to Amit Panjwani, DM, MD, DNB, MBBS, Department of Internal Medicine, Pulmonary Medicine Unit, Salmaniya Medical Complex, Manama, 351, Kingdom of Bahrain. Tel: +973 35684578; E-mail: drameetp@gmail.com

Received 27 October 2018

Accepted 25 November 2018

The Egyptian Journal of Internal Medicine  
2019, 31:243–246

Upper airway obstruction (UAO) is a dangerous condition that is associated with significant mortality. It is easily diagnosed when its presentation is acute, but subacute or chronic presentation may pose a diagnostic dilemma resulting in disastrous consequences. Clinical evaluation may provide subtle clues towards its presence, whereas pulmonary function test can provide useful information to confirm the presence and site of UAO. Relevant radiological and endoscopic investigation may then be carried out to identify the exact etiology and institute appropriate therapy. We present a case of chronic UAO that was detected with the help of pulmonary function test and confirmed with computed tomography and endoscopy. The etiology was found to be related to fibrosis of the larynx resulting in the immobility of the vocal cords secondary to radiotherapy given to the patient 7 years ago. This is an unusual presentation, as most of the radiotherapy-related fibrosis in the head and neck region present within a few months of the exposure to radiation.

## Keywords:

delayed complication, pulmonary function test, radiotherapy, upper airway obstruction

Egypt J Intern Med 31:243–246

© 2019 The Egyptian Journal of Internal Medicine

1110-7782

## Introduction

Pulmonary function has been assessed in humans for around two hundred years. Pulmonary function tests (PFTs) have evolved gradually over time and more so in the last 7 decades with the improvement in the field of electronics. They have found themselves an important place in the diagnostic assessment of patients with respiratory symptoms and abnormal clinical and/or radiological chest findings. PFTs are used for screening patients at risk of pulmonary diseases, for preoperative evaluation and for assessing the prognosis of lung diseases. They are also used in monitoring the efficacy of treatment and detecting adverse effects of medication on the lungs. Upper airway obstruction (UAO) is an umbrella term used to include functional and anatomical narrowing of the large upper airways like the larynx, extrathoracic/intrathoracic trachea and lobar bronchi [1]. The UAO may present acutely, which may be life-threatening, and deserves to be treated immediately. Subacute to chronic presentations occurring over days to months may result in a misdiagnosis, and its correct identification is necessary to institute appropriate measures to relieve the UAO. PFTs play a crucial role in these settings to identify the problem, locate the site of narrowing, and guide the use of confirmatory tests to achieve an accurate diagnosis. We present a rare case of UAO that was detected with the help of PFT and confirmed on imaging and endoscopic examination.

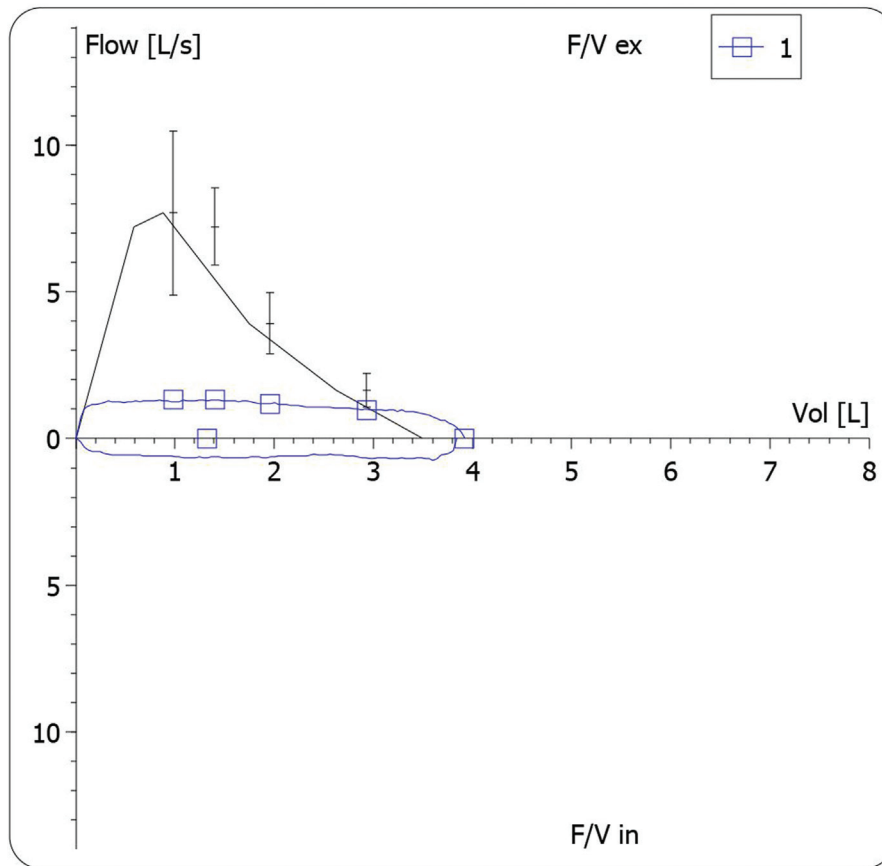
## Case report

A 28-year-old man presented with a history of exertional dyspnea, cough with mucoid expectoration and noisy breathing for the last 4 months. He denied hemoptysis, chest pain, weight loss, or anorexia. He was diagnosed with nasopharyngeal carcinoma and treated with chemoradiotherapy 7 years ago. He was unable to provide further details with regard to the staging and duration of therapy. On examination, the patient was in mild respiratory distress, although the oxygenation was normal. He was afebrile and had no significant cervical lymphadenopathy. Respiratory system examination revealed the use of accessory muscles. Auscultation showed both inspiratory and expiratory wheezing heard over the chest with the loudest intensity appreciated in the neck. His speech was muffled, and he had a thick, fibrosed skin of the neck. The other systemic examination was unremarkable. Complete blood count, biochemical profile, urinalysis and electrocardiogram were normal. Radiograph of the chest was also normal. Spirometry showed a 'box pattern' on flow-volume loop (FVL) (Fig. 1) and 'straight' forced expiratory spirogram with the loss of the usual curvature (Fig. 2).

This is an open access journal, and articles are distributed under the terms of the Creative Commons Attribution-NonCommercial-ShareAlike 4.0 License, which allows others to remix, tweak, and build upon the work non-commercially, as long as appropriate credit is given and the new creations are licensed under the identical terms.

Figure 1

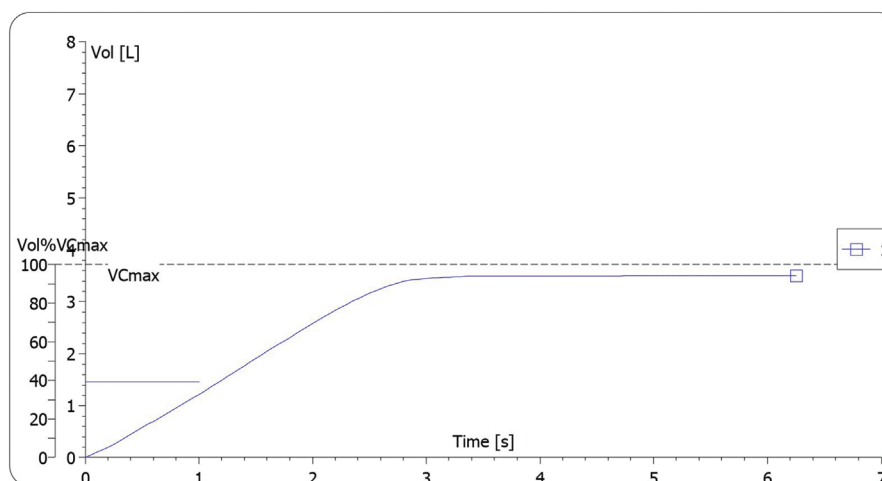
## Flow-Volume



Spirometry shows a 'box pattern' on flow-volume loop.

Figure 2

## Time Volume



Spirogram (volume vs. time graph) showing a straight line, in contrast to the usual curvature.

The Empey index was 16.6, the ratio of maximal expiratory flow at 50% of vital capacity ( $FEF_{50}$ ) and maximal inspiratory flow at 50% of vital capacity ( $FIF_{50}$ ) was 1.81, ratio of forced expiratory volume in 1 s ( $FEV_1$ )

to forced expiratory volume in 0.5 s ( $FEV_{0.5}$ ) was 1.9 and  $FIF_{50}$  was 39 l/min. These findings were consistent with fixed UAO. The patient was then subjected to fiberoptic laryngoscopy, which revealed the true vocal

cords fixed in the paramedian position on both sides with a narrow glottic chink of 3 mm. In addition, the view of the larynx was unhealthy with the mucosa appearing pale and fibrosed. The contrast-enhanced computed tomography of the neck showed narrowing of the laryngeal vestibule, whereas the computed tomography of the chest showed no significant abnormality. Our patient was taken up for a bilateral laser cordectomy and has improved symptomatically at the time of last follow-up.

---

## Discussion

UAO is caused by neoplasia, scars, skeletal–facial malformations, infections, inflammatory conditions, and trauma. The exact prevalence of UAO in the general population is unknown. In a study carried out in a PFT laboratory of an academic medical center, prevalence of UAO in patients who underwent spirometry was 7.5% [2]. Obstruction of the upper and lower respiratory tract may present with similar symptoms like dyspnea and noisy breathing. Asthma and chronic obstructive pulmonary disease are common causes of lower airway obstruction and may falsely be assumed to be the cause of the patient's symptoms [3]. Therefore, subacute and chronic presentation of UAO may result in delayed or wrong diagnosis. Airways have to be significantly compromised before symptoms appear. Exertional dyspnea usually develops when the airway diameter has reduced to 8 mm, whereas dyspnea at rest and stridor develop when the diameter has reduced to 5 mm. Stridor is heard mainly during inspiration and is prominent over the neck, whereas wheeze is heard mainly during expiration. Interestingly, sound recordings from the neck and chest show similar sound frequencies in asthmatic wheeze and stridor, thereby leading to incorrect diagnosis.

Physiological abnormalities on spirometry appear after more than 80% of the airway lumen is compromised. Numerical values obtained during spirometry are useful for diagnosing UAO. Ratio of  $FEV_1$  to peak expiratory flow of greater than 10 ml/l/min (based on the criteria of Empey [4]), ratio of  $FEF_{50}/FIF_{50}$  of less than 0.3 or greater than 1,  $FIF_{50}$  of less than 100 l/min and ratio of  $FEV_1$  to  $FEV_{0.5}$  greater than 1.5 are the quantitative criteria commonly used in the diagnosis of UAO [2].

FVL is commonly used to diagnose and identify the site of airway stenosis [5,6]. Miller and Hyatt [5] have described three distinct patterns of UAO on FVL: variable extrathoracic obstruction, variable intrathoracic obstruction and fixed obstruction. The fixed lesions may be caused by laryngeal or tracheal

strictures, extensive laryngeal or tracheal tumors, cricoarytenoid ankylosis and extensive mediastinal disease. Variable extrathoracic UAO may be caused by cord paralysis, laryngomalacia, localized laryngeal tumor or granuloma, whereas variable intrathoracic UAO may be caused by tracheochondromalacia, foreign body and localized tracheal tumor or granuloma. Variable extrathoracic obstruction is associated with flow limitation and flattening in the inspiratory limb of the FVL, whereas variable intrathoracic obstruction is associated with flow limitation and flattening of the expiratory limb of the FVL. Fixed obstruction in the upper airways is associated with no change in the caliber of the airways during different phases of respiration, resulting in flattening of both the expiratory and inspiratory portion of the FVL, giving rise to the 'box pattern' [7]. The spirogram shows a 'straight line' in the UAO, as the flow becomes constant in the early part of the expiration [8]. Relying on any one parameter may be misleading; therefore, appearances of the FVL, spirogram and upper airway indices should be taken into account for the diagnosis of UAO. Recurrent laryngeal nerve palsy is a common cause of immobility of the vocal cords [9]. Radiotherapy to the head and neck region is associated with mucositis, skin reactions, soft tissue fibrosis and perichondritis of the larynx. Fibrosis is a known early complication seen in these patients, occurring in the first few months, but it is unusual to see this delayed complication after several years of radiotherapy [10]. In our patient, he presented with respiratory distress and clinical features of airway obstruction. The presentation was chronic, and it made it difficult for us to suspect UAO, as it is usually suspected in patients presenting acutely. The PFT showed Empey index more than 10,  $FEF_{50}/FIF_{50}$  greater than 1,  $FEV_1/FEV_{0.5}$  greater than 1.5 and  $FIF_{50}$  ( $<100$  l/min) suggesting the presence of UAO. The FVL and spirogram confirmed the presence of fixed type of UAO. The endoscopy and radiological investigations confirmed these findings. The fibrosis of the laryngeal abductor muscles and the fixity of the cricoarytenoid joint induced by radiotherapy was the possible cause of the fixed vocal cords. It is very unusual to see such a delayed presentation of fibrosis secondary to radiotherapy after so many years.

---

## Conclusion

UAO is a life-threatening condition that may present a diagnostic dilemma, especially if it has a subacute or chronic presentation. Some clues may be available on the medical history and clinical examination. The quantitative criteria (mentioned above) and FVL obtained with the help of spirometry is a simple,

noninvasive and a specific way of arriving at a diagnosis of UAO and limiting the differential diagnostic possibilities. Relevant radiographic and endoscopic evaluation may then be performed to identify the exact cause of UAO and institute appropriate treatment. Fibrosis of the larynx secondary to radiotherapy may have a delayed presentation after several years, and clinicians should be aware of this life-threatening possibility.

#### Financial support and sponsorship

Nil.

#### Conflicts of interest

There are no conflicts of interest.

---

#### References

- 1 Pellegrino R, Viegi G, Brusasco V, Crapo RO, Burgos F, Casaburi R, *et al.* Interpretative strategies for lung function tests. *Eur Respir J* 2005; 26:948–968.
- 2 Modrykamien AM, Gudavalli R, McCarthy K, Liu X, Stoller JK. Detection of upper airway obstruction with spirometry results and the flow-volume loop: a comparison of quantitative and visual inspection criteria. *Respir Care* 2009; 54:474–479.
- 3 Golish JA, Ahmad M, Yarnal JR. Chronic upper airway obstruction. Methods of detection and recognition. *Cleve Clin Q* 1980; 47:9–15.
- 4 France JE, Thomas MJC. Clinical use of the Empey index in the emergency department. *Emerg Med J* 2004; 21:642–643.
- 5 Miller RD, Hyatt RE. Evaluation of obstructing lesions of the trachea and larynx by flow-volume loops. *Am Rev Respir Dis* 1973; 108:475–481.
- 6 Guntupalli KK, Bandi V, Sirgi C, Pope C, Rios A, Eschenbacher W. Usefulness of flow volume loops in emergency center and ICU settings. *Chest* 1997; 111:481–488.
- 7 Karkhanis VS, Desai U, Joshi JM. Flow volume loop as a diagnostic marker. *Lung India* 2013; 30:166–168.
- 8 Gibson GJ. Central airway obstruction and bronchial carcinoma. In: Gibson GJ, editor. *Clinical tests of respiratory function*. 3rd ed. New Delhi: Jaypee Brothers; 2009. 221–234.
- 9 Eckel HE, Sittel C. Bilateral recurrent laryngeal nerve paralysis. *HNO* 2001; 49:166–179.
- 10 Prepageran N, Raman R. Delayed complication of radiotherapy: laryngeal fibrosis and bilateral vocal cord immobility. *Med J Malaysia* 2005; 60:377–378.