

A case of Ewing's sarcoma presenting with massive pleural effusion

Anupam Patra^a, Amiya Kumar Dwari^a, Susmita Kundu^b, Ritika Jha^b

^aDepartment of Pulmonary Medicine, N.R.S. Medical College, ^bDepartment of Pulmonary Medicine, R.G. Kar Medical College, Kolkata, West Bengal, India

Correspondence to Anupam Patra, MD (Pulmonary Medicine), DNB Assistant Professor, Department of NRS Medical College, Kolkata, India, Tel: 03364510341; e-mail: dranupam.patra@gmail.com

Received 10 February 2016

Accepted 28 February 2016

The Egyptian Journal of Internal Medicine 2016, 28:86–89

A 16-year-old girl presented with swelling and heaviness on the right side of her chest and progressive dyspnoea since 20 days. Radiological examination revealed a mass lesion in the right lower zone with right-sided massive pleural effusion and rib erosion. Histopathology and immunohistochemistry were suggestive of Ewing's sarcoma. We reported this case because of the uncommon presentation of this rare tumour and its associated pleural effusion. Early diagnosis of this case led to favourable outcomes.

Keywords:

Ewing's sarcoma, female, pleural effusion

Egypt J Intern Med 28:86–89

© 2016 The Egyptian Journal of Internal Medicine 1110-7782

Introduction

Ewing's sarcoma (ES) is a malignant neoplasm that accounts for about 1% of all childhood cancers and primarily involves the bone or soft tissue [1]. It is the second most common malignant bone tumour after osteosarcoma with a male to female ratio of 55 : 45 [2]. The most common age at diagnosis is the second decade of life, although 20–30% of cases are diagnosed in the first decade. These tumours mostly arise from the long bones but can arise from virtually any bone or soft tissue [2]. Its appearance in people under 20 years of age is very rare (less than three in one million). We report a case of ES in a 16-year-old girl who presented with a chest wall mass causing pleural effusion without any complaints of pain at the local site.

Case summary

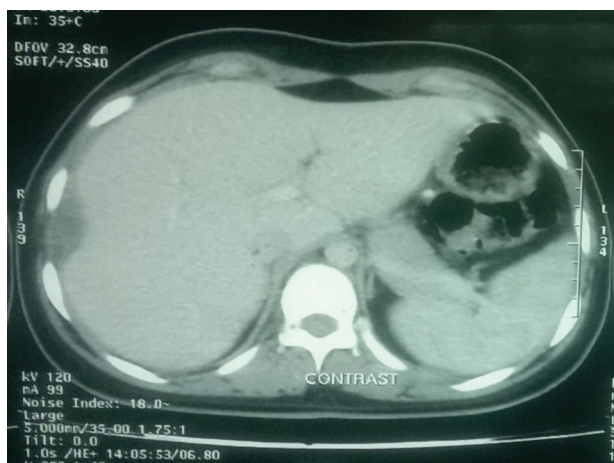
A 16-year-old female student presented at our OPD with swelling and heaviness on the right side of her chest along with exertional shortness of breath since 20 days. There was no history of fever or chest pain.

On examination the patient was found to be conscious, alert, and cooperative. General survey showed only pallor. Her blood pressure was 110/76 mmHg, Respiration rate (RR) was 24/min and pulse was 96/min. Her routine laboratory analysis was within normal limits, except for the presence of mild anaemia (Hb; 8.2 g%). Examination of the respiratory system revealed a swelling in the right lower part of the chest wall in the infra-axillary and infrascapular region with diminished movements on the right hemithorax. Percussion note on the entire right hemithorax was stony dull. Vocal fremitus, breath sounds and vocal resonance were diminished in the same region.

Her chest radiograph showed homogeneous opacity in the right hemithorax with obliteration of cardiophrenic and costophrenic angle and shift of the mediastinum to the opposite side (Fig. 2). Ultrasonography of the thorax showed a 9×7.4 cm heterogeneous hyperechoic Space occupying lesion (SOL) in the right lower zone with huge pleural effusion and downward displacement of the right hemidiaphragm and liver. Diagnostic thoracentesis revealed a haemorrhagic lymphocytic exudative pleural effusion that was negative for malignant cells (total cell count: 30/μl, mainly lymphocytes at 90%; proteins: 3.8 g/dl; glucose: 53 mg/dl; lactate dehydrogenase: 392 IU/l; adenosine deaminase: 10.6 U/l). The total serum protein and albumin concentrations were 7.2 and 4.4 g/dl, respectively. Contrast enhanced computed tomography (CECT) of the thorax showed a sclerotic right ninth rib with erosion, surrounded by a large necrotic mass lesion, right-sided massive pleural effusion, and compression over the right lobe of the liver (Fig. 3–4). Computed tomography-guided Fine needle aspiration cytology (FNAC) from the mass lesion showed small round tumour cells with the possibility of being small cell lung carcinoma or ES. Computed tomography-guided trucut biopsy was performed, which was suggestive of malignant round cell tumour compatible with ES/primitive neuroectodermal tumour (Fig. 5). Immunohistochemistry was strongly positive for CD99 (membranous) and negative for CD45, desmin, synaptophysin and myogenin (Fig. 6–7). Fibreoptic

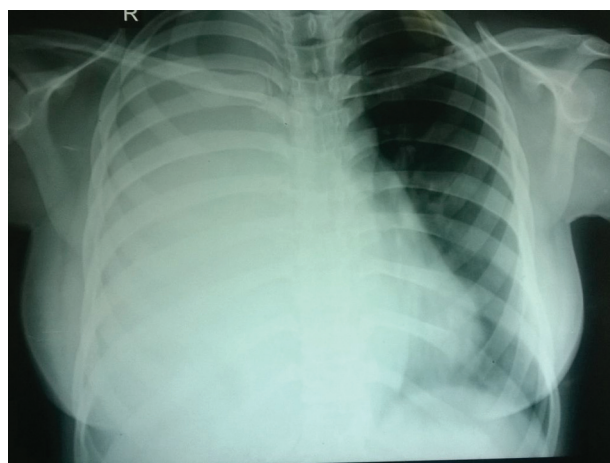
This is an open access article distributed under the terms of the Creative Commons Attribution-NonCommercial-ShareAlike 3.0 License, which allows others to remix, tweak, and build upon the work noncommercially, as long as the author is credited and the new creations are licensed under the identical terms.

Figure 1



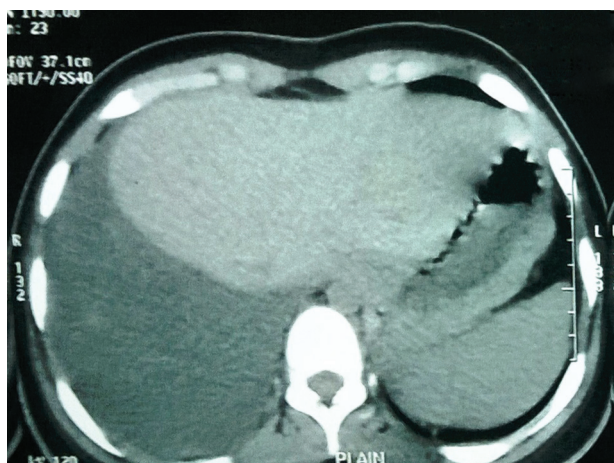
CECT of the thorax showing regression of tumour after two cycles of chemotherapy.

Figure 2



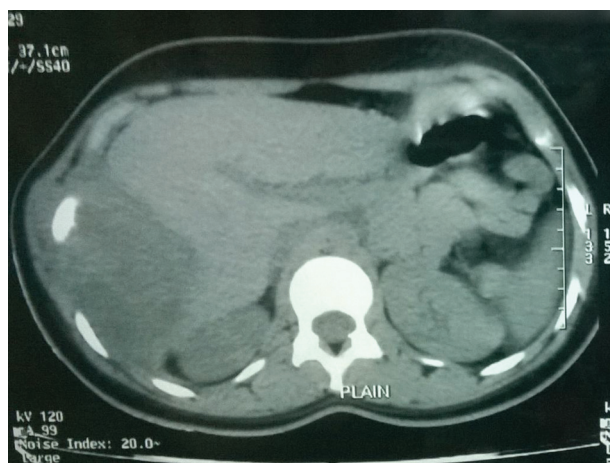
Chest radiograph showing homogeneous opacity in the right hemithorax with obliteration of cardiophrenic and costophrenic angle and shift of the mediastinum to the opposite side.

Figure 3



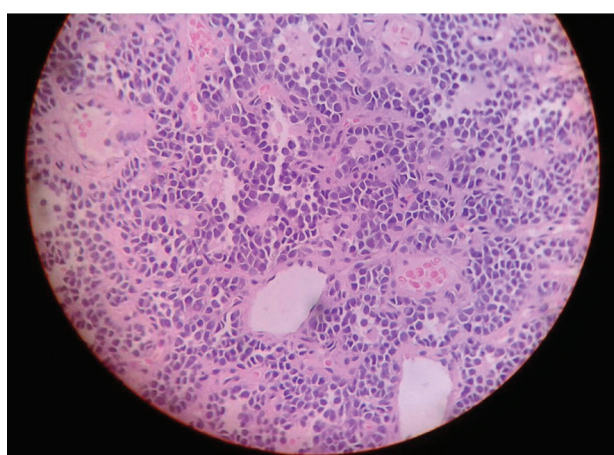CECT of the thorax showing right-sided massive pleural effusion.

Figure 4



CECT of the thorax showing sclerotic right ninth rib with erosion, surrounded by a large necrotic mass lesion, right-sided massive pleural effusion and compression over the right lobe of the liver.

Figure 5



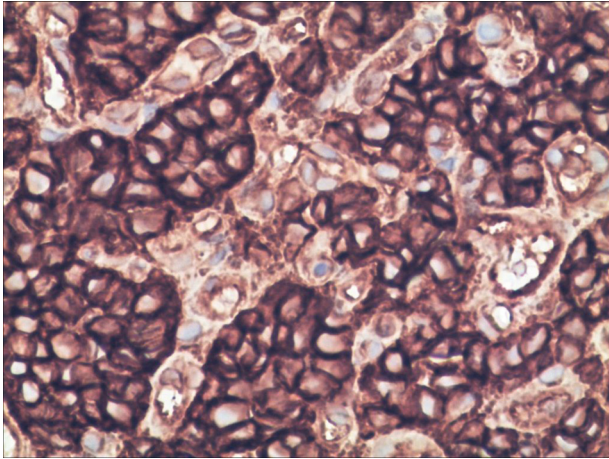
Trucut biopsy from the mass showing uniform round cells having hyperchromatic nuclei, inconspicuous nucleoli and scanty cytoplasm with areas of necrosis characteristic of malignant round cell tumour compatible with Ewing's sarcoma/primitive neuroectodermal tumour (PNET).

bronchoscopy did not show any abnormality and the Bronchoalveolar lavage (BAL) fluid study was essentially within normal limits.

Radionuclide whole-body bone scan showed moderately increased concentration of radiotracer over the ninth rib anterolaterally with no significant abnormal focal concentration of radiotracer suggestive of metastasis.

On the basis of these findings, the diagnosis of ES of the ninth rib with extension into the thoracic cavity causing pleural effusion was confirmed. We referred the case to the radiotherapy department where she received a chemotherapy regimen with injection vincristine, doxorubicin, cyclophosphamide, ifosfamide and

Figure 6



Immunohistochemistry strongly positive for CD99 (membranous).

etoposide. After two cycles of chemotherapy, there was clinical and radiological improvement and the patient is currently awaiting surgery (Fig. 1).

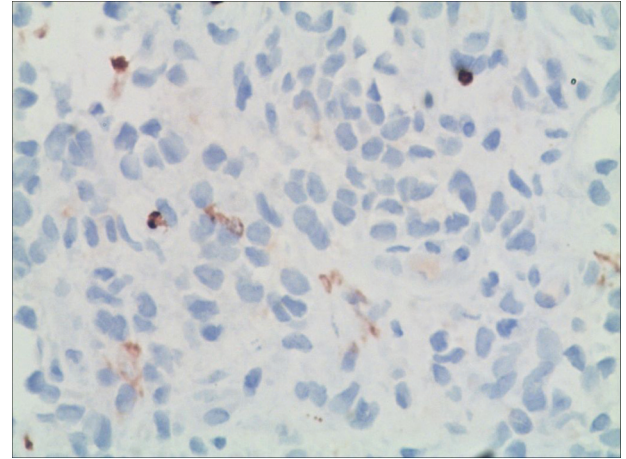
Discussion

ES was first described by James Ewing in 1921 as a 'diffuse endothelioma of the bone' [3]. ES is the second most common malignant bone tumour, after osteosarcoma. The male to female ratio is 55 : 45 [2]. They present mostly in the second decade of life. ES family of tumours include ES, Askin's tumour and primitive neuroectodermal tumours. These tumours mostly arise from the long bones but can arise from virtually any bone or soft tissue. These tumours not only have a similar cellular physiology but also a shared chromosomal translocation [t(11; 22)]. In ESFTA characteristic chromosomal translocation (11; 22) (q24; q12) can be detected in 90% of cases [4].

The most common presentations are local pain and swelling. Compression symptoms may arise depending on the site at which the tumour is present. Patients with chest wall or pelvic mass may experience significant complaints at a very late stage. Systemic features like fever, weight loss, anaemia, leucocytosis and an increase in erythrocyte sedimentation rate (ESR) are not frequently seen unless the disease is quite advanced. Presentation of pleural effusion as in our case is an unusual finding [5].

ES of the ribs has propensity to spread towards the thoracic cavity and manifests as an extra pleural mass. Radiologically it is described as a central, diaphyseal, lytic tumour that has an onion-skin periosteal reaction

Figure 7



Immunohistochemistry negative for CD45.

mostly affecting long bones and/or associated with soft-tissue mass. The affected rib is predominantly lytic in most cases, but mixed lytic-sclerotic and even predominantly sclerotic patterns are also encountered [6]. Our patient exhibited mixed lytic-sclerotic pattern in the ninth rib (right side).

Before the era of chemotherapy, fewer than 10% of patients with ES survived. Patients commonly died of metastases within 2 years, indicating the need for systemic treatment. With the use of modern multimodal therapeutic regimens including combination chemotherapy, surgery and radiotherapy a cure rate of 50% and more can be achieved [7].

The presence of metastatic disease is the worst prognostic factor. Those with isolated pulmonary metastases have a slightly better outcome (~30% survive) than those with bone or bone marrow metastases at initial diagnosis (20% or less) [8,9].

Persistence of ES-specific RNA in the bone marrow after treatment may be unfavourable. Children below 10 years of age do somewhat better than older patients [9]. The size and location of disease are often inter-related. Pelvic lesions have a lesser chance of survival [9,10]. The response to initial therapy may also predict the outcome [10]. Ewing's tumour is a very rare malignant tumour that accounts for about 1% of all childhood cancers. Involvement of the chest wall along with massive pleural effusion by this tumor is also rare. Early diagnosis and prompt initiation of therapy improves the outcome from the disease.

Financial support and sponsorship

Nil.

Conflicts of interest

There are no conflict of interest.

References

- 1 Iwamoto Y. Diagnosis and treatment of Ewing's sarcoma. *Jpn J Clin Oncol* 2007; 37:79–89.
- 2 Bernstein M, Kovar H, Paulussen M, Randall RL, Schuck A, Teot LA, Juergens H. Ewing's sarcoma family of tumors: current management. *Oncologist* 2006; 11:503–519.
- 3 Ewing J. Diffuse endothelioma of bone, *Proc NY Pathol Soc* 1921; 21:17.
- 4 Amatruda JF, Tran K, Mantel M, Singer S, Demetri G. Diagnosis in oncology. *Askin tumor. J Clin Oncol* 1998; 16:1997–1998.
- 5 Wolf G, Aigner RM, Schwarz T. Massive pleural effusion with dyspnea in a 17-year-old boy as the first sign of ewing sarcoma. *J Pediatr Hematol Oncol* 2002; 24:420.
- 6 Franken EA Jr, Smith JA, Smith WL. Tumors of the chest wall in infants and children. *Pediatr Radiol* 1977; 6(1):13–18.
- 7 Craft A, Cotterill S, Malcolm A, Spooner D, Grimer R, Souhami R, *et al.* Ifosfamide-containing chemotherapy in Ewing's sarcoma: The Second United Kingdom Children's Cancer Study Group and the Medical Research Council Ewing's Tumor Study. *J Clin Oncol* 1998; 16:3628–3633.
- 8 Cotterill SJ, Ahrens S, Paulussen M, Jürgens HF, VoÛte PA, Gadner H, Craft AW. Prognostic factors in Ewing's tumor of bone: analysis of 975 patients from the European Intergroup Cooperative Ewing's Sarcoma Study Group. *J Clin Oncol* 2000; 18:3108–3114.
- 9 Grier HE, Krailo MD, Tarbell NJ, Link MP, Fryer CJ, Pritchard DJ, *et al.* Addition of ifosfamide and etoposide to standard chemotherapy for Ewing's sarcoma and primitive neuroectodermal tumor of bone. *N Engl J Med* 2003; 348:694–701.
- 10 Paulussen M, Ahrens S, Dunst J, Winkelmann W, Exner GU, Kotz R, *et al.* Localized Ewing tumor of bone: final results of the cooperative Ewing's Sarcoma Study CESS 86. *J Clin Oncol* 2001; 19:1818–1829.