

Wonderful drug for walking pneumonia: oseltamivir

Faheem Arshad, Suhail Mantoo, Umar H. Khan

Department of Internal and Pulmonary
Medicine, Sher-i-Kashmir Institute of Medical
Sciences (SKIMS), Srinagar, Jammu and
Kashmir, India

Egypt J Intern Med 26:97–98
© 2014 The Egyptian Journal of Internal Medicine
1110-7782

Correspondence to Faheem Arshad, MD,
133 Housing Colony, Sanatnagar, Rawalpura
Lane 5, Srinagar 190005, Jammu and Kashmir,
India
Tel: +91 941 907 5281; fax: 01942488069;
e-mail: faheem2285@gmail.com

Received 15 May 2014

Accepted 12 July 2014

The Egyptian Journal of Internal Medicine

2014, 26:97–98

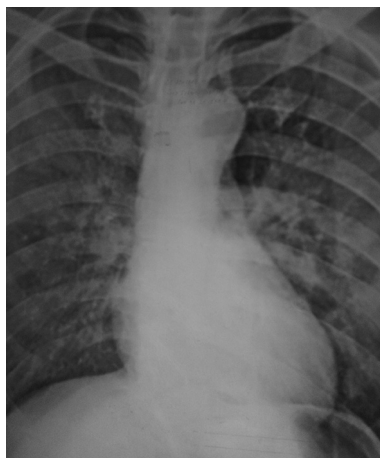
Atypical pneumonia constitutes significant proportion of community-acquired pneumonia with viruses being the least common etiology in adults. The most common etiologies of viral pneumonia in adults include influenza virus, adenovirus, parainfluenza virus, etc. Infection with influenza viruses (A, B, and C) occurs in distinct outbreaks every year. Although a self-limited infection (uncomplicated influenza), its atypical presentation can lead to delay in diagnosis and increased morbidity and mortality in certain high-risk groups (complicated influenza).

A 50-year-old man, farmer by occupation, with no underlying comorbid condition was referred to our tertiary care institute with presenting complains of low-grade fever, continuously associated with rigors and chills relieved by analgesics, with associated history of generalized aches and pains with myalgias and sore throat for 7 days. He denied any history of chest pain, breathlessness, orthopnea, vomiting, or diarrhea. Before referral, he had received antibiotics in the form of ceftriaxone and levofloxacin without any improvement. General physical examination revealed mild pallor; rest was unremarkable. His vitals were pulse of 110/min, blood pressure of 110/72 mmHg, and temperature of 100°F. Chest examination revealed bronchial breathing associated with bilateral coarse crackles in inframammary area. Cardiovascular, abdominal, and central nervous system examination were normal. Laboratory evaluation revealed normal hemogram along with leukocyte count. Liver function tests were normal. His creatine phosphokinase (CPK) and lactate dehydrogenase (LDH) were high. ECG was normal. Chest radiography (posteroanterior view) revealed bilateral midzone infiltrates (Fig. 1). Ultrasonography of the abdomen was normal. In view of atypical presentation with normal counts

and high CPK and LDH and midzone interstitial infiltrates on chest radiograph, nasopharyngeal swab was taken, PCR of which revealed positivity for H1N1 influenza A virus. C-reactive protein levels were low (10 mg/l). Patient was initiated on oseltamivir (75 mg) twice a day for 5 days along with oral hydration, hand wash, and analgesics in the form of paracetamol. Patient showed a marked improvement in his symptoms with progressive decrease in CPK and LDH and subsidence of infiltrates on chest radiography compared with radiography before receiving oseltamivir (Fig. 2).

Influenza virus infection leads to cell death, impairs T cells, neutrophil, and macrophage function, resulting in impairment of host defenses, and may lead to bacterial infection of normally sterile areas, including the lower respiratory tract. Influenza virus A has two envelope glycoproteins, hemagglutinin (H) and neuraminidase (N); hemagglutinin initiates infectivity by binding to cellular sialic acid residues and the neuraminidase cleaves newly synthesized virus from sialic acid on cell surfaces, allowing spread of the virus to other cells. Although declared as pandemic by the WHO, current epidemic of H1N1 viral infection has affected countries across the world. Despite antigenic shifts and drifts, neuraminidase inhibitor oseltamivir is active against influenza A and B virus [1] and has been approved for both prophylaxis and treatment in individuals at least 1 year of age. Oseltamivir causes entrapment of virus inside the infected respiratory epithelial cells and prevent spread to other cells. For severe influenza pneumonia not responding to antibiotics, it should be given, even after the 48-h window as in our patient who improved markedly clinically and radiologically. Usually, it is well tolerated with exception of few side effects including gastrointestinal complaints [2] and

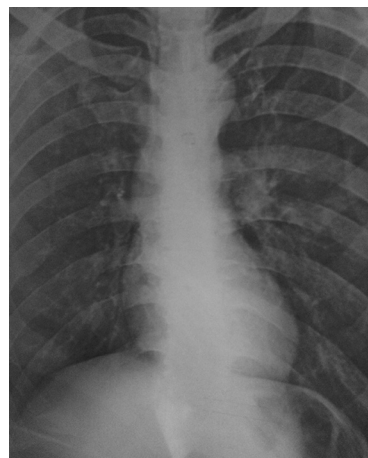
Figure 1



Chest radiography (posteroanterior view) showing bilateral midzone interstitial infiltrates.

rare neuropsychiatric manifestations [3]. Recently, oseltamivir resistance has emerged with mechanism being mutations resulting in amino acid substitutions in active sites of the neuraminidase, resulting in drug-specific resistance, the common being H274Y mutation [4]. Although newer drugs are available and have a different safety profile and lower potential for inducing resistance, they are much more expensive and efficacy is still not proved. Hence, we believe oseltamivir should still be used as first line in H1N1 influenza infection until testing for resistance is available, as clinical and radiological improvement was seen in present case with atypical pneumonia with influenza A virus after treatment with oseltamivir.

Figure 2



Postoseltamivir chest radiography (posteroanterior view) showing marked resolution of interstitial infiltrates.

Acknowledgements

Conflicts of interest

There are no conflicts of interest.

References

- 1 Treanor JJ, Hayden FG, Vrooman PS, Barbarash R, Bettis R, Riff D, *et al.* Efficacy and safety of the oral neuraminidase inhibitor oseltamivir in treating acute influenza: a randomized controlled trial. US Oral Neuraminidase Study Group. *JAMA* 2000; 283:1016–1024.
- 2 Strong M, Burrows J, Stedman E, Redgrave P. Adverse drug effects following oseltamivir mass treatment and prophylaxis in a school outbreak of 2009 pandemic influenza A (H1N1) in June 2009, Sheffield, United Kingdom. *Euro Surveill* 2010; 15:14–19, pii/19565.
- 3 Pollack A. *Childhood deaths in Japan bring new look at flu drug*: New York Times; 2005.
- 4 Moscona A. Global transmission of oseltamivir-resistant influenza. *N Engl J Med* 2009; 360:953.