Mahran et al. The Egyptian Journal of Internal Medicine (2021) 33:13
https://doi.org/10.1186/s43162-021-00044-1

The Egyptian Journal of Internal Medicine

CASE REPORT Open Access

Neglected reactive arthritis complicated by bilateral hip and temporomandibular joints ankylosis after a suspected tetanus infection: a case report

Mohamed A. Mahran[1], Ahmed A. Khalifa[2*], Mohamed Eslam Elsherif[3] and Omar Refai[1]

Abstract

Background: Reactive arthritis had been reported to occur after various vaccinations, including the tetanus toxoid vaccine; here, we report a case of ankylosing arthropathy suggested to be a complication of missed neglected reactive arthritis after tetanus infection.

Case presentation: A healthy 20-year-old woman presented with subtrochanteric right femoral fracture; imaging studies showed bilateral ankylosed hip, kyphoscoliosis, bilateral fused temporomandibular joints, and normal sacroiliac joints bilaterally. Laboratory investigations for a rheumatic or autoimmune disease were all within normal ranges. Detailed history revealed admission of the patient to an ICU unit (1 year before the trauma) for a month as she was diagnosed as having tetanus infection, after which she was unable to walk or feed herself. At the final follow-up, the patient started walking with a moderate limb after having a series of surgeries including femoral fracture fixation, temporomandibular joint excision arthroplasty, and bilateral total hip arthroplasty.

Conclusion: Unusual complications after tetanus infection can occur in the form of joint ankylosis, which could be presented after prolonged immobilization possibly due to improper management of reactive arthritis.

Keywords: Ankylosis, Locked jaw, Reactive arthritis, Tetanus

Background

Tetanus infection is caused by *Clostridium tetani*, which is a gram-positive, spore-forming anaerobic bacillus; infection route may be through skin laceration or a direct inoculation by contaminated surgical instruments [1]. The commonest form is generalized tetanus, occurring in about 80% of cases, which can be presented clinically by locked jaws, risus sardonicus, generalized muscle spasms, and back muscle spasm (opisthotonus) which may lead to respiratory distress [2].

Reactive arthritis (ReA) is a rare non-purulent joint inflammation condition with unknown exact etiology [3]; however, it was reported to be associated with various types of infection (upper respiratory, gastrointestinal, and urogenital) [4]. Development of ReA had been reported after administration of various vaccinations, including influenza, rabies, bacillus Calmette–Guerin (BCG), and tetanus vaccines in few case reports [5–8]; however, to the best of our knowledge, it had not been reported after a tetanus infection.

The diagnosis of ReA can easily be missed owing to the variability of its clinical presentation [3]; it could be complicated by joint destruction, which may lead to fibrous ankylosis [3, 4]. The joint stiffness may be worsened if the patient was admitted to the intensive care

* Correspondence: ahmed_adel0391@med.svu.edu.eg; https://www.svu.edu.eg
[2]Orthopaedic and Traumatology Department, Qena University Hospital, South Valley University, Kilo 6 Qena-Safaga Highway, Qena 83523, Egypt
Full list of author information is available at the end of the article

unit (ICU) for an extended period without joints mobilization [9, 10].

Case presentation

A 20-year-old female presented to the emergency department in May 2016 with acute pain and swelling of the right proximal thigh after falling on the ground. Initially, history was obtained regarding the mechanism of trauma and past medical comorbidities. The patient's relatives revealed that in June 2015, the patient had a forearm abscess, which was drained at a local hospital. After about 10 days, she developed an attack of tonic-colonic convulsions, upon which she was admitted to the ICU for a month. She was diagnosed as having tetanus (they have no documentation to prove the diagnosis); after discharge from the ICU, the patient had stiffness of both lower limbs with difficulty in walking (became wheelchair-bound) and the inability to mouth feeding (upon which the patient received an endogastric tube for feeding). Initial physical examination in the emergency department revealed an external rotation and shortening of the right lower limb, apparent flexion deformity of the left hip with painless limited movement in all directions, and facial deformity. The patient was stable, and after consultation with a maxillofacial surgeon, a series of imaging studies were obtained in the form of lateral plan radiographs for the cervical and lumbar spine, anteroposterior (AP) radiographs for the pelvis and right hip, and a skull computed tomography (CT) (Fig. 1). The patient was diagnosed as having bilateral locked temporomandibular joints (TMJ), bilateral fused hip, right subtrochanteric femoral fracture, and kyphoscoliosis deformity of the spine.

The patient was transferred to the inpatient ward for consultation with a rheumatologist regarding the patient's history and the atypical affection of the hip joints and spine. He suggested the possibility of a seronegative spondylarthritis; however, laboratory investigations in the form of anti-nuclear antibody, HLA-B27, uric acid, hemoglobin, C3 and C4 complement, alanine aminotransferase, aspartate aminotransferase, sodium, potassium, urea, creatinine, urine analysis, and glucose were all within their normal ranges. Pelvis AP plan radiograph showed normal sacroiliac joints bilaterally. Based on the physical and laboratory examination and the absence of any other possible etiology, the diagnosis was made as post tetanus neglected ReA complicated by bilateral hip and bilateral TMJ bony ankylosis.

On the sixth day post-admission, under nasotracheal intubation, general anesthesia, open reduction and internal fixation (ORIF) for the right subtrochanteric fracture using a 90° condylar blade plate (CBP) was performed (Figs. 1c and 2a). The second team of maxillofacial surgeons performed excision arthroplasty of the TMJ; the surgery went uneventfully. The patient was discharged on the 5th day postoperative.

Follow-up at 2 weeks, 6 weeks, 3 months, and 6 months revealed no complications with fracture union started to be noticed in the serial follow-up radiographs.

At 1 year follow-up, the right subtrochanteric fracture achieved complete union; the patient started assisted weight-bearing and sought advice for having surgery to mobilize both hips; she was advised to have a left total hip arthroplasty (THA) first then to have a staged right THA.

Cementless THA for the left hip was performed in August 2017 using a 36-ceramic head (Fig. 2a). Up to 6 months follow-up; the patient had no complications. In February 2018, the patient was scheduled for a staged right THA; metal removal was performed as the 1st stage (Fig. 2b), and then after 3 months (May 2018), the patient had a right THA (Fig. 2c). At the final follow-up, the radiographs showed an acceptable position of both THA with the progression of the spinal deformity (Fig. 3); however, the patient was satisfied with the results of the surgeries; she is now talking and eating properly and walking without assistance with a moderate limb.

Discussion

Joint ankylosis can be either intra-articular (true) or extra-articular (false); the latter can be bony or fibrous,

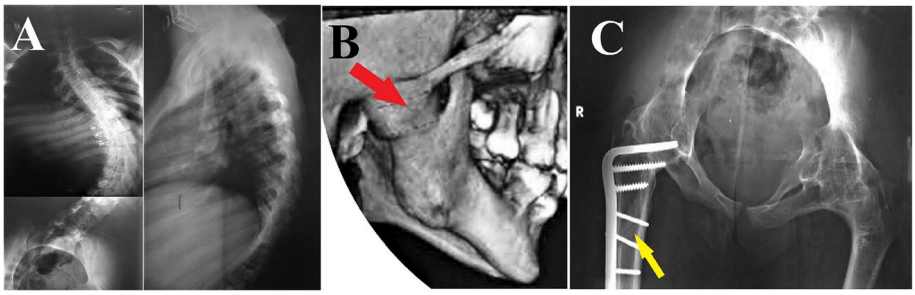

Fig. 1 Serial imaging studies performed in the emergency department. **a** Plan radiograph of the spine showing kyphoscoliosis deformity. **b** Skull CT showing fusion of the temporomandibular joint (red arrowhead). **c** Right femur subtrochanteric fracture fixed with a plate (fracture line indicated by the yellow arrowhead)

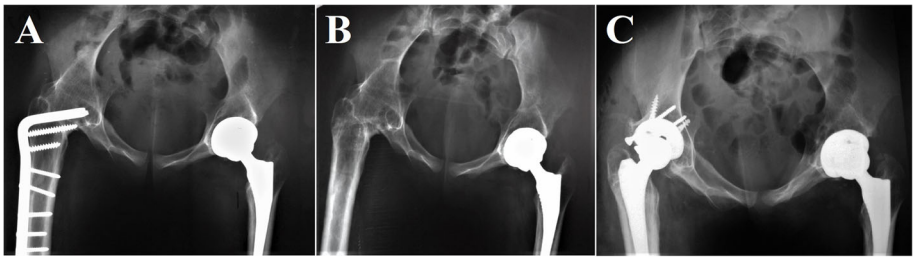

Fig. 2 Stages of hip reconstruction surgery. **a** Union of the right subtrochanteric fracture and THA of the left hip. **b** Removal of the right CBP as a first stage for right hip THA. **c** THA of the right hip with acetabulum reconstruction

which may originate as a result of joint surface insult following trauma or infection or as sequelae of prolonged immobilization [11]. In a study by Clavet et al. [9], they reported that about 40% of the patients who were admitted to ICU for more than 2 weeks developed a contracture in several joints, including the hips, if they were not routinely mobilized during ICU admission.

Our theory for explaining the current case is that the patient had a tetanus infection upon which she was admitted to the ICU; she probably developed ReA, which was missed and complicated with joint ankylosis (first started as fibrous then converted to bony) due to prolonged immobilization in the ICU; this was concluded after excluding other causes which may lead to the same presentation, mainly the seronegative spondylarthritis commonly occurring as ankylosing spondylitis [12], which was excluded by the normal laboratory investigations as well as the absence of sacroiliac joint affection.

The establishment of a definite diagnosis of ReA is difficult as the condition may pass unnoticed [3], as apart from elevated ESR and CRP during acute febrile illness, there are no specific laboratory tests or biomarkers to confirm the diagnosis [4, 13]. In our case, this was the only possible diagnosis that we could reach by exclusion after having a normal laboratory investigation.

Tetanus toxoid, which is a purified preparation of inactivated tetanus toxin [14], had been reported to cause ReA in some patients [6]; the clinical presentation can be asymptomatic; in some cases, oligoarthritis of large joints can occur [4]. Schmitt SK reported that lower extremity joint affection is more common in ReA; in chronic untreated cases, some patients can develop a

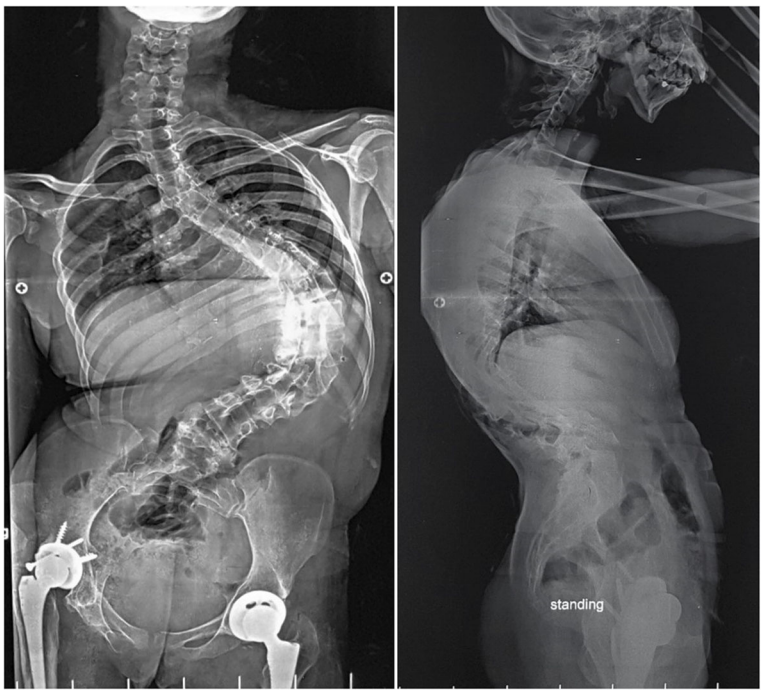

Fig. 3 Final follow-up radiographs of the pelvis and the spine, showing the proper position of the total hip prosthesis, a progression of the spinal deformity, and preservation of the sacroiliac joints

clinical picture that mimics ankylosing spondylitis [13]. Post tetanic spine deformity in the form of kyphosis was reported in an old case report by A. G. Quinlan [15]; he explained the occurrence of the deformity by the multiple vertebral crush fractures due to spasmodic hyperextension caused by tetanus. However, in the current case, spinal deformity may had occurred as a compensatory mechanism to the stiff pelvis caused by the bilaterally ankylosed hip [16].

As the vaccine itself is considered an imitation of infection to stimulate the immune response [17], we proposed that the reported mechanism behind the development of ReA after tetanus vaccination [5–8] is the cause of the joint affection in the current case report. Although the exact mechanism by which vaccination trigger ReA is not fully understood [5], however, some theories were postulated to explain this reaction, as the vaccine itself may trigger reactive events in genetically susceptible individuals as it may resemble a host antigen leading to the activation of an autoimmune response which may be enhanced by HLAB27 [6]; however, the expression of HLAB27 is positive in about 75% of the cases [18]; the rest of the cases may be negative as the finding in the current case report.

The stiffness of the joints may be aggravated by the prolonged recumbency, lack of physiotherapy, and the patient's dependence on nasogastric tube feeding, which may lead to the TMJ immobilization for an extended period. We tried to track the ICU doctors who were responsible for the case while she was admitted to the ICU; however, we failed; we tried to contact the hospital to get any information from the medical reports of the patient; we also failed. As we mainly relied on the history given by the patient family for what occurred from the start of her ICU admission till the appearance in our hospital, we could not decide if the whole condition developed during the ICU stay or it started in the ICU and was aggravated by the negligence of physiotherapy and proper care after the patient was discharged. We reached this "possible" diagnosis by exclusion, as this was the most probable scenario in light of all the information collected.

Conclusion

ReA can occur as a complication of tetanus infection with large joint affection, which, if not correctly discovered and treated, could be complicated by joint ankylosis which may be aggravated by prolonged immobilization.

Abbreviations

ReA: Reactive arthritis; ICU: Intensive care unit; AP: Anteroposterior; CT: Computed tomography; TMJ: Temporomandibular joints; ORIF: Open reduction and internal fixation; CBP: Condylar blade plate; THA: Total hip arthroplasty

Acknowledgements

We would like to thank our colleges in the rheumatology department in our hospital for their great guidance and advice helping us to formulate the diagnosis for the current case.

Authors' contributions

O.R. and M.A.M. carried out the idea as well as performing the surgeries. A.A.K. and M.E.E. carried out the data acquisition and assessment. A.A.K., M.E.E., and O.R. did the literature search, drafted the manuscript, and designed the figures. O.R. and M.A.M. did the critical revision. All authors discussed the results and commented on the manuscript. All authors read and approved the final manuscript.

Funding

We did not receive any specific grant from funding agencies in the public, commercial, or not-for-profit sectors.

Availability of data and materials

All the data regarding the presented case are included within the article.

Declarations

Competing interest

The authors declare that they have no competing interests.

Ethics approval and consent to participate

The ethical committee of our institution waived ethical approval for this case report as this was considered a part of the usual patients' care (Faculty of Medicine, Assiut University, Egypt (Telephone, Fax: + 20882332278, ethics-committee12@yahoo.com, http://afm.edu.eg).

Consent for publication

A verbal as well as an informed written consent was obtained from the patient herself to use her clinical data and images for publication of this case report, and verbal consent was taken from her family; no identification of the patients' identity is present neither in the manuscript nor in the images.

Author details

[1]Orthopaedic Department, Assiut University Hospital, Assiut, Egypt.
[2]Orthopaedic and Traumatology Department, Qena University Hospital, South Valley University, Kilo 6 Qena-Safaga Highway, Qena 83523, Egypt.
[3]Orthopaedic Department, Student's Hospital, Assiut University, Assiut, Egypt.

Received: 5 January 2021 Accepted: 26 April 2021
Published online: 11 May 2021

References

1. Finkelstein P, Teisch L, Allen CJ, Ruiz G (2017) Tetanus: a potential public health threat in times of disaster. Prehosp Disaster Med 32(3):339–342. https://doi.org/10.1017/S1049023X17000012
2. Bae C, Bourget D (2020) Tetanus. In: StatPearls. StatPearls Publishing Copyright© 2020. StatPearls Publishing LLC., Treasure Island (FL)
3. Pennisi M, Perdue J, Roulston T, Nicholas J, Schmidt E, Rolfs J (2019) An overview of reactive arthritis. JAAPA 32(7):25–28. https://doi.org/10.1097/01.JAA.0000558320.47868.2f
4. Garcia-Kutzbach A, Chacon-Suchite J, Garcia-Ferrer H, Iraheta I (2018) Reactive arthritis: update 2018. Clin Rheumatol 37(4):869–874. https://doi.org/10.1007/s10067-018-4022-5
5. Sahin N, Salli A, Enginar AU, Ugurlu H (2009) Reactive arthritis following tetanus vaccination: a case report. Mod Rheumatol 19(2):209–211. https://doi.org/10.1007/s10165-008-0140-2
6. Kaul A, Adler M, Alokaily F, Jawad AS (2002) Recurrence of reactive arthritis after a booster dose of tetanus toxoid. Ann Rheum Dis 61(2):185. https://doi.org/10.1136/ard.61.2.185
7. Kesiktaş FN, Yemisen M, Gün K, Uludağ M, Dernek B (2015) A case of reactive arthritis developed after tetanus vaccine. İstanbul Kanuni Sultan Süleyman Tıp dergisi 7(3):147–149. https://doi.org/10.5222/iksst.2015.147
8. Maillefert JF, Tonolli-Serabian I, Cherasse A, Demoux AL, Tavernier C, Piroth L (2000) Arthritis following combined vaccine against diphtheria, polyomyelitis, and tetanus toxoid. Clin Exp Rheumatol 18(2):255–256

9. Clavet H, Hebert PC, Fergusson D, Doucette S, Trudel G (2008) Joint contracture following prolonged stay in the intensive care unit. CMAJ 178(6):691–697. https://doi.org/10.1503/cmaj.071056
10. Koester K, Troeller H, Panter S, Winter E, Patel JJ (2018) Overview of intensive care unit-related physical and functional impairments and rehabilitation-related devices. Nutr Clin Pract 33(2):177–184. https://doi.org/10.1002/ncp.10077
11. Vaishya R, Singh AK, Agarwal AK, Vijay V (2018) Bilateral spontaneous bony ankylosis of the elbow following burn: a case report and review of the literature. J Orthop Case Rep 8(5):43–46. https://doi.org/10.13107/jocr.2250-0685.1204
12. Zochling J, Smith EU (2010) Seronegative spondyloarthritis. Best Pract Res Clin Rheumatol 24(6):747–756. https://doi.org/10.1016/j.berh.2011.02.002
13. Schmitt SK (2017) Reactive arthritis. Infect Dis Clin N Am 31(2):265–277. https://doi.org/10.1016/j.idc.2017.01.002
14. Kroger AT, Pickering LK, Wharton M, Mawle A, Hinman AR, Orenstein WA (2015) Immunization. In: Bennett JE, Dolin R, Blaser MJ (eds) Mandell, Douglas, and Bennett's principles and practice of infectious diseases. W.B. Saunders, Philadelphia, pp 3516–3553.e3515. https://doi.org/10.1016/b978-1-4557-4801-3.00321-0
15. Quinlan A (1954) Post-tetanic kyphosis: report of a case. J Bone Joint Surg Br Vol 36(1):80–83
16. Buckland AJ, Steinmetz L, Zhou P, Vasquez-Montes D, Kingery M, Stekas ND, Ayres EW, Varlotta CG, Lafage V, Lafage R, Errico T, Passias PG, Protopsaltis TS, Vigdorchik J (2019) Spinopelvic compensatory mechanisms for reduced hip motion (ROM) in the setting of hip osteoarthritis. Spine Deformity 7(6): 923–928. https://doi.org/10.1016/j.jspd.2019.03.007
17. Sell S (2019) How vaccines work: immune effector mechanisms and designer vaccines. Expert Rev Vaccines 18(10):993–1015. https://doi.org/10.1080/14760584.2019.1674144
18. Adachi JA, D'Alessio FR, Ericsson CD (2000) Reactive arthritis associated with typhoid vaccination in travelers: report of two cases with negative HLA-B27. J Travel Med 7(1):35–36. https://doi.org/10.2310/7060.2000.00010

Publisher's Note